

The ameliorative effect of olive oil on arsenic induced hepatic gross and qualitative histological changes in albino rats

Hira Waqas Cheema¹, Shabana Ali², Huma Beenish³, Tooba Khurshid⁴

ABSTRACT

Objective: To evaluate the ameliorative effect of olive oil on gross and qualitative histological changes induced by arsenic in liver of albino rats.

Study Design: An experimental/observational study

Place and Duration: Department of Anatomy, Islamic International Medical College, Riphah International University, Islamabad from 1st November, 2017 to 18th April, 2018.

Methodology: A total of 45 adult albino rats were selected and fifteen out of 45 rats were placed in each of three cages. Rats of group I (control group) were given distilled water, group II received sodium arsenite (40 mg per kg per day) and group III were given 0.2 ml per day of olive oil along with sodium arsenite for 30 days. Rats were dissected after 30 days to observe gross and qualitative histological changes in liver i.e. appearance, colour, consistency and weight along with histological changes like necrosis, congestion and hemorrhage.

Results: Among gross parameters all rats in group I (control) showed spongy appearance, dark brown colour and firm consistency. Group II rats showed white necrosed appearance, soft consistency and all rats in group III have normal spongy, pale brown liver with few white patches and soft to firm consistency. Group II livers showed increased mean weight of 10.19 grams as compared to group I liver (7.83 grams) and mean liver weight of group II rats was 7.83 grams. Among qualitative histological parameters, necrosis, congestion and haemorrhage were observed. None of rats in control group I showed these changes, in group II 100% of rats showed necrosis and congestion whereas 46% of rats showed haemorrhage. The use of olive oil has significantly reduced necrosis to 53.3 % and congestion to 46.7% of rats in group III, whereas no haemorrhage was observed in group III rats.

Conclusion: The olive oil improves gross and qualitative histological changes induced by arsenic in liver which include appearance, colour, consistency, weight, congestion, necrosis and haemorrhage.

Keywords: Albino rat, Liver, Olive oil, Oleuropin, Sodium arsenite, Gross changes, Microscopic changes

How to Cite This:

Cheema HW, Ali S, Beenish H, Khurshid T. The ameliorative effect of olive oil on arsenic induced hepatic gross and qualitative histological changes in albino rats. *Isra Med J.* 2019; 11(4): 213-217.

This is an Open Access article distributed under the terms of the Creative Commons Attribution-Noncommercial 4.0 International License (<http://creativecommons.org/licenses/by-nc/4.0/>), which permits unrestricted use, distribution, and reproduction in any medium, provided the original work is properly cited.

INTRODUCTION

Arsenic is one of the toxic metals which have toxic effects on liver. The weight of liver is about 1.5 kg, which is largest organ of our body. Its main functions include metabolism, energy production, storage of vitamins, trace elements and iron, and production of bile. The rat liver weighs about 5 % of body weight whereas human liver is only 2 to 3 % of body weight¹. Arsenic being a toxic metal affects mitosis, cellular respiration and enzymes².

Arsenic produces oxidizing radicals like reactive oxygen and reactive nitrogen species which can cause necrosis as well as damage to lipids, DNA and proteins in cells³. Arsenic causes inflammation leading to acute changes which can ultimately become chronic even leading to cancer⁴. There are various organs in body mainly liver, kidney and heart can be affected by arsenic⁵. The hormonal system of our body is affected by exposure to inorganic arsenic for long period of time⁶. It can also produce toxic influence on and reproductive system and

1. Senior lecturer of Anatomy
2. Associate Professor of Anatomy
3. Assistant Professor of Anatomy
4. Postgraduate Trainee of Anatomy

Islamic International Medical College,
Riphah International University, Islamabad

Correspondence:

Hira Waqas Cheema
Senior lecturer of Anatomy, Islamic International Medical
College, Riphah International University, Islamabad
Email: hira.cheema@hotmail.com

Received for Publication: August 20, 2019

1st Revision of Manuscript: September 11, 2019

2nd Revision of Manuscript: September 16, 2019

Accepted for Publication: September 18, 2019

nervous system⁷. The weight of body is also lost due to chronic exposure⁸. Arsenic can also lead to chronic inflammation of liver leading to hepatic fibrosis as well as diabetes⁶. Other diseases caused by arsenic include cancer of skin, gangrene of toes and chronic lung disease⁶. Moreover ovaries and testes of rats are also found to be affected by arsenic⁷.

A list of antioxidants are available which can prevent various organs from oxidative damage but olive oil is one of them which can have hepatoprotective effects. Olive oil is composed of 70% oleic acid and phenolic compounds including oleuropein which have many health advantages. Among various seed oils olive oil has greater antioxidant power⁹. The use of antioxidants can prevent toxic effects of arsenic on various organs. Toxicity of arsenic on ovary has been improved by use of calcium, Vitamin E, and olive oil⁹. Curcumin and selenium are included in list of antioxidants being used to ameliorate toxic effects of arsenic on liver of rats^{10,11}. Among phenolic compounds of olive oil, the antioxidant effect of oleuropein is observed to be effective in literature, therefore use of olive oil in our study may prevent toxic effects of arsenic on liver¹². Extra virgin olive oil (EVOO) has more effective antioxidant role for liver because of high content of oleuropin^{13,14}. Arsenic in drinking water is current issue in Pakistan.

According to WHO, about 150 million people around the world rely on groundwater contaminated with arsenic. About 10 µg per liter arsenic is permissible in drinking water according to WHO guidelines, but the government of Pakistan says that 50 µg per liter is acceptable. A new study shows that 50-60 million people living in the Indus valley are drinking water which very likely exceeds their government's safe level¹⁵. As olive oil has antioxidant properties, this study was conducted to prove its ameliorative effect on liver. Therefore, we conducted this study with an objective to evaluate ameliorative effect of olive oil on arsenic induced gross and qualitative histological changes in liver of albino rats.

METHODOLOGY

This experimental/ observational study was conducted at Department of Anatomy, Islamic International Medical College, Riphah International University from 1st November 2017 to 18th April 2018. In this study, 15 out of total 45 male albino rats kept in each of the three cages. The weight of each rat was 250 to 300 grams. Only male rats of age 2 to 4 months were included whereas female rats and those with known disease were excluded. Animals were divided into three groups of 15 rats each. Control group (Group I) rats consumed distilled water as drinking. Rats in Group II consumed a solution of arsenic (40mg/kg) as sodium arsenite for 4 weeks. However, those in group III consumed a solution of arsenic (40mg/kg) as sodium arsenite along with olive oil 0.2ml/day for 4 weeks. All rats from these groups were dissected after four weeks and their livers were observed for gross changes which include appearance, colour, consistency and they were weighed on weighing machine. Then they were placed in containers having 10 percent formaline. The longitudinal sections were taken from left lateral and right lateral lobes.

After fixation and embedding, histological slides were prepared with hematoxylin and eosin staining. The slides were examined under high magnification of X40 in light microscope to observe microscopic qualitative changes which include congestion, necrosis and haemorrhage. Congestion in hepatic sinusoids was observed as blood accumulated in them, necrosis in hepatic parenchyma was observed as there was loss of hepatic architecture and haemorrhage was present if blood comes out of endothelial lining into hepatic parenchyma.

Data Analysis: Data was analyzed in SPSS version 22. Mean and standard errors were calculated for the quantitative variables. In order to compare qualitative or categorical variables, Chi square test was used. The mean comparison of quantitative variables between group I and experimental groups II and III was obtained by applying one way ANOVA. The multiple comparison of groups was obtained by applying post Hoc tukey test. A p value of equal to or less than 0.05 was considered as significant value.

RESULTS

Appearance of liver: All livers of group I showed normal spongy appearance on cross section. In group II, 100 % of liver showed complete white appearance might be due to necrosis and in group III 100 % of liver showed few patchy white areas with normal spongy architecture. The simultaneous use of olive oil and arsenic has saved the livers to become completely white in appearance. The p value was 0.000 which was significant as it was less than 0.05 (Fig-1). It was calculated by chisquare test.




Fig-1. Gross appearance of livers.

In Group-I dark brown colour with normal spongy architecture, Group-II liver is white necrosed in appearance whereas Group-III liver only shows few white patches along with normal spongy architecture.

Colour of liver: The colour of all livers of rats of control group (Group-I) was dark brown as chocolate. In Group-II, 100% of the livers had white colour as cheese whereas 100 % of rats of Group-III had pale brown colour. The white colour might be due to necrosis caused by arsenic and pale brown colour showed olive oil has prevented the change in colour of rat livers caused by arsenic in Group-III. The p value was 0.000 which was significant according to chisquare test.

Table-I: Frequency of mean weight of livers and multiple comparison of weight in grams among control and experimental groups. (N=45)

Groups	Mean weight (gm)	SEM	p value	Comparison	Mean difference	p value
Group I (n=15)	7.68	0.4459	0.000	I vs II	2.513	0.000
Group II (n=15)	10.19	0.4459		I vs III	0.149	0.940
Group III (n=15)	7.83	0.4459		II vs III	2.363	0.000
p value	0.000*					

Table-II: Frequency of congestion in central vein and sinusoids, necrosis and haemorrhage in hepatic parenchyma (N=45)

Groups	Qualitative parameters						Total
	Congestion		Necrosis		Haemorrhage		
	Present n(%)	Absent n(%)	Present n(%)	Absent n(%)	Present n(%)	Absent n(%)	
Group I (n=15)	0 (0%)	15 (100%)	0 (0 %)	15 (100%)	0 (0%)	15 (100 %)	15
Group II (n=15)	15 (100%)	0 (0%)	15 (100%)	0 (0%)	7 (46%)	8 (53 %)	15
Group III(n=15)	7 (46%)	8 (53%)	8 (53.3%)	7 (46%)	0 (0%)	15 (100 %)	15
Total	22 (49 %)	23 (51%)	23 (51%)	22 (49%)	7 (15%)	38 (84 %)	45
P value	0.000						

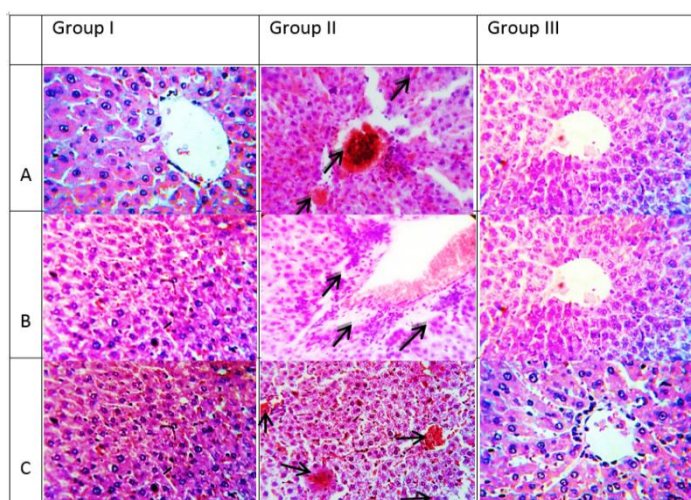
Consistency of liver: The consistency of livers of control group (Group-I) was normal which was neither soft nor firm. 100% of livers of Group-II had soft consistency whereas 100% of livers of Group-III showed soft as well as normal consistency. The white part showed soft consistency whereas part of liver with normal spongy architecture had normal consistency. In this way, olive oil had significantly prevented the soft consistency of liver caused by arsenic in Group-III. The p value was 0.000 which was significant.

Weight of liver: Mean weight of rat liver in control Group-I was 7.68 g while in experimental Group-II it was increased to 10.19 g. In Group-III, mean weight was 7.83 g which is very close to the normal weight of livers of control group. This proves that olive oil has significantly reverted the increase in weight caused by arsenic in Group-III. The difference in mean weight of two experimental groups was significant but mean difference between control Group-I and III was insignificant which shows that weight of Group-III was reduced by use of olive oil such that it was almost same as normal weight of control Group-I.

Congestion in sinusoids and central vein: No congestion was seen in central vein and sinusoids of control group. All experimental rats in Group-II showed sinusoidal and central vein congestion whereas only 46.7% of rats showed congested sinusoids and central vein in Group-III. In short Olive oil has significantly prevented the rats of Group-III to develop congestion in their vessels. P value was 0.000.

Necrosis in hepatic parenchyma: The experimental rats of Group-I had normal parenchyma while all rats of group II were found to have necrosis in the parenchyma of their livers. Olive oil given in Group-III had prevented the rats to develop parenchymal necrosis such that only 53.3% of them showed necrosis P value (0.00).

Haemorrhage in hepatic parenchyma: In Group-I, hepatic parenchyma appeared to be normal, 46% of rats in group II showed haemorrhage. In Group-III, olive oil has markedly improved haemorrhage as it was absent in all rats. (Table-II) (Figure-2C).

**Fig-2: Group wise distribution of congestion in central vein and sinusoids, necrosis and haemorrhage in hepatic parenchyma.**

(A) Showing normal sinusoids and central vein, congestion in central vein and sinusoid in Group-II L4B, whereas no congestion in Group-III L3C, (B) Showing normal parenchyma in Group-I L7D, presence of coagulative necrosis in periportal areas in Group-II L5B absence of necrosis in Group-III, (C) showing normal parenchyma in Group-I, haemorrhage in hepatic parenchyma in Group-II L5C and absence of haemorrhage in Group-III L3A (H and E, X 40).

DISCUSSION

In the present study appearance, colour, consistency and weight of livers were observed. The appearance and colour of liver was observed in control and experimental groups of study. All livers of group I showed normal spongy appearance on cross section. In group II, all livers showed complete white necrosed appearance and in group III 100 % of liver showed few patchy necrosed areas with normal spongy architecture. The white necrosed appearance is due to necrosis which is the result of inflammation caused by toxins or viruses.^[16] The simultaneous use of olive oil and arsenic has improved the complete white necrosed appearance to patchy necrosed appearance in group III. Rana et al showed that liver of rats appeared to be white

necrosed due to chronic use of arsenic¹⁷. Similarly another study of Choinier also showed that liver showed swollen appearance with loss of spongy architecture¹⁸.

The colour of all livers of rats of control group was dark brown. In group II, 100% of the livers had white colour whereas 100 % of rats of group III had pale brown colour. The white colour is due to necrosis caused by arsenic. In one of study by Tan et al, arsenic caused chronic inflammation of liver and gross appearance of liver showed white necrotic foci. The variations in the colour of patches from light yellow, dark red and brown were remarkable¹⁹. A study by Bhattacharya proved that intraperitoneal injection of 1.5mg per kg of sodium arsenite for 30 days caused white necrotic appearance of liver²⁰. The white colour of liver is due to necrosis. As use of olive oil prevents necrosis therefore it prevents the change in colour of liver.

Mean weight of rat liver in control group I was 7.68 g while in experimental group II it was increased to 10.19 g. In group III, mean weight was 7.83 g which is almost same as the normal weight of livers of control group. This proves that olive oil has significantly prevented the increase in weight caused by arsenic in group III. The increase in weight of liver is caused by arsenic due to the acute inflammation causing enlargement of hepatocytes and increase in diameter of hepatic sinusoids²¹. The same result is supported by one of the studies in which the weight of rat livers was increased due to exposure to arsenic for 3 weeks¹¹. Liver weight shows a significant increase in another study by Adil due to hepatic toxicity induced by arsenic and improved weight gain by improving effect of naringin²². A study conducted by Olusegun also showed an increase in liver and brain weight due to the combined exposure of arsenic and di-(ethylhexyl) phthalate²³. Against the result of this study, it was found that the weight of the liver did not change after 8 weeks of exposure to sodium arsenite in a study conducted by Souza et al.² This is because a longer duration of exposure to arsenic causes chronic inflammation and fibrosis that cause the contraction of the liver and decreases the weight. The use of olive oil has significantly maintained the normal weight of liver as it prevents the process of inflammation of liver caused by arsenic due to its antioxidant effect.

Inflammation of liver caused acute inflammation of liver and congestion is first sign of inflammation appearing in sinusoids followed in central vein²⁴. Oyagbemi et al in their study used arsenic in different doses to three groups for the period of 28 days, congestion was observed in sinusoids and central vein of liver³. Azab conducted his study in which olive leaf extract was given. The congestion caused by use of carbendazim was significantly reduced due to olive leaf extract²⁵. As a result of ischemia caused by passive venous congestion of sinusoids, degeneration of hepatocytes take place leading to necrosis of hepatic parenchyma.

In our study, there is normal parenchyma in control group whereas use of olive oil in group III has reduced necrosis to only 53.3% of rats. Zonal necrosis was observed in zone I periportal as well as zone III pericentral which is least oxygenated. Olive oil in group III limit necrosis to only pericentral zone. Das in his study also used 40mg per kg of sodium arsenite in drinking water to mice for 30 days and he also observed periportal necrosis²⁶.

Ogun used oleuropin in dose of 30mg per kg along with 5mg per kg of sodium arsenite only for 15 days and observed that only 6 rats showed necrosis in arsenic group whereas necrosis was found in only 1 rat due to use of Oleuropin²⁷.

The haemorrhage is late event in acute inflammation of liver caused by arsenic caused by spillage of blood into parenchyma due to damage to endothelium of blood vessels. 46% of rats in group II showed haemorrhage which was reduced due to use of olive oil in group III such that none of rat showed haemorrhage.²⁸ Yang in his study used As₂O₃ (arsenic trioxide) through intraperitoneal route in a low dose of 3mg per kg for only 2 weeks, the haemorrhage was observed in their liver parenchyma²⁹. Azab proved in his study that use of olive leaf extract had significantly reduced parenchymal haemorrhage caused by Cardendazim²⁵.

In light of comparison with various studies, present study is supported as gross changes of appearance, colour and consistency has been improved. Olive oil due to its antioxidant properties improved its appearance close to that of control rat livers. The soft consistency of liver due to arsenic use was also found to become firm due to use of olive oil. The studies were also observed in which increase in weight of livers by arsenic was prevented by use of olive oil. In the same way various studies were found in literature in which use of oleuropin or olive leaves have improved the microscopic changes which include congestion in sinusoids, necrosis and haemorrhage in hepatic parenchyma due to inflammation of liver.

CONCLUSION

The olive oil improves gross and qualitative histological changes induced by arsenic in liver which include appearance, colour, consistency, weight, congestion, necrosis and haemorrhage.

CONTRIBUTION OF AUTHORS

Cheema HW: Conceived idea, Designed research methodology, Data analysis, Manuscript writing

Ali S: Manuscript final reading and approval

Beenish H: Manuscript drafting, Data compilation and analysis

Khurshid T: Literature review, Data analysis

Disclaimer: None.

Conflict of Interest: None.

Source of Funding: None.

REFERENCES

- García-Chávez E, Santamaría A, Díaz-Barriga F, Mandeville P, Jiménez-Capdeville ME. Arsenite-induced formation of hydroxyl radical in the striatum of awake rats. *Brain Res.* 2003; 976(1): 82–89.
- Souza A, Marchesi SC, de Almeida Lima GD, Machado-Neves M. Effects of Arsenic Compounds on Microminerals Content and Antioxidant Enzyme Activities in Rat Liver. *Biol Trace Elem Res.* 2017; 183(2): 305–313.
- Oyagbemi AA, Omobowale TO, Asenuga ER, Afolabi JM,

- Adejumobi OA, Adedapo AA, et al. Effect of arsenic acid withdrawal on hepatotoxicity and disruption of erythrocyte antioxidant defense system. *Toxicol Reports*. 2017; 4 (1): 521–529.
4. Iwama K, Nakajo S, Aiuchi T, Nakaya K. Apoptosis induced by arsenic trioxide in leukemia U937 cells is dependent on activation of p38, inactivation of ERK and the Ca²⁺-dependent production of superoxide. *Int J Cancer*. 2001; 92(4): 518–526.
5. Al-Forkan M, Islam S, Akter R, Shameen AS, Khaleda L, Rahman Z, et al. A Sub-Chronic Exposure Study of Arsenic on Hematological Parameters, Liver Enzyme Activities, Histological Studies and Accumulation Pattern of Arsenic in Organs of Wistar Albino Rats. *J Cytol Histo*. 2016; 07(02): 1-7.
6. Tseng CH, Tai TY, Chong CK, Tseng CP, Lai MS, Lin BJ, et al. Long-term arsenic exposure and incidence of non-insulin-dependent diabetes mellitus: a cohort study in arseniasis-hyperendemic villages in Taiwan. *Environ Health Perspect*. 2000; 108(9): 847–851.
7. Sanghamitra S, Hazra J, Upadhyay SN, Singh RK, Amal RC. Arsenic induced toxicity on testicular tissue of mice. *Indian J Physiol Pharmacol*. 2008; 52(1): 84–90.
8. Nandi D, Patra RC, Swarup D. Effect of cysteine, methionine, ascorbic acid and thiamine on arsenic-induced oxidative stress and biochemical alterations in rats. *Toxicology*. 2005; 211(1–2): 26–35.
9. Jhala DD, Chinoy NJ, Rao MV. Mitigating effects of some antidotes on fluoride and arsenic induced free radical toxicity in mice ovary. *Food Chem Toxicol*. 2008; 46(3): 1138–1142.
10. Sankar P, Telang AG, Kalaivanan R, Karunakaran V, Manikam K, Sarkar SN. Effects of nanoparticle-encapsulated curcumin on arsenic-induced liver toxicity in rats. *Toxicol Ind Health*. 2016; 32(3): 410–421.
11. Shafik NM, El Batsh MM. Protective Effects of Combined Selenium and Punica granatum Treatment on Some Inflammatory and Oxidative Stress Markers in Arsenic-Induced Hepatotoxicity in Rats. *Biol Trace Elem Res*. 2016; 169(1): 121–128.
12. El-bakry K, Toson E, Serag M, Aboser M. Hepatoprotective Effect of Moringa Oleifera Leaves Extract Against Carbon Tetrachloride- Induced Liver. *World Pharma and Pharmaceut Sci*. 2016; 5(5): 76–89.
13. Jurado-Ruiz E, Varela LM, Luque A, Berná G, Cahuana G, Martinez-Force E, et al. An extra virgin olive oil rich diet intervention ameliorates the nonalcoholic steatohepatitis induced by a high-fat “Western-type” diet in mice. *Mol Nutr Food Res*. 2017; 61(3): 1–12.
14. Santangelo C, Vari R, Scazzocchio B, De Sanctis P, Giovannini C, D'Archivio M, et al. Anti-inflammatory Activity of Extra Virgin Olive Oil Polyphenols: Which Role in the Prevention and Treatment of Immune-Mediated Inflammatory Diseases? *Endocr Metab Immune Disord Targets*. 2018; 18(1): 36–50.
15. Sanjrani MA, Teshome M, Sanjrani ND, Leghari SJ, Moryani HT, Shabnam AB. Current Situation of Aqueous Arsenic Contamination in Pakistan, Focused on Sindh and Punjab Province, Pakistan: A Review. *J Pollut Eff Cont*. 2017; 5(4): 1-8.
16. Baratta JL, Ngo A, Lopez B, Kasabwalla N, Longmuir KJ, Robertson RT. Cellular organization of normal mouse liver: a histological, quantitative immunocytochemical, and fine structural analysis. *Histochem Cell Bio*. 2009; 131(6): 713–726.
17. Rana T, Bera AK, Das S, Bhattacharya D, Pan D, Das SK. Inhibition of oxidative stress and enhancement of cellular activity by mushroom lectins in arsenic induced carcinogenesis. *Asian Pacific J Cancer Prev*. 2016; 17(9): 4185–4197.
18. Choiniere J, Lin MJ, Wang L, Wu J. Deficiency of pyruvate dehydrogenase kinase 4 sensitizes mouse liver to diethylnitrosamine and arsenic toxicity through inducing apoptosis. *Liver Res*. 2018; 2(2): 100–107.
19. Tan M, Schmidt RH, Beier JI, Watson WH, Zhong H, States JC, et al. Chronic subhepatotoxic exposure to arsenic enhances hepatic injury caused by high fat diet in mice. *Toxicol Appl Pharmacol*. 2011; 257(3): 356–364.
20. Bhattacharya A, Dhar P, Mehra RD. Preliminary morphological and biochemical changes in rat liver following postnatal exposure to sodium arsenite. *Anatomy & Cell Biology*. 2012; 45(4): 229–240.
21. Maronpot RR, Yoshizawa K, Nyska A, Harada T, Flake G, Mueller G, et al. Hepatic enzyme induction: histopathology. *Toxicol Pathol*. 2010; 38(5): 776–795.
22. Adil M, Kandhare AD, Visnagri A, Bodhankar SL. Naringin ameliorates sodium arsenite-induced renal and hepatic toxicity in rats: decisive role of KIM-1, Caspase-3, TGF- β , and TNF- α . *Ren Fail*. 2015; 37(8): 1396–1407.
23. Olusegun KA, Regina NU, Oladipo A. Combined arsenic and di-(2-ethylhexyl) phthalate exposure elicits responses in brain ATPases different from hepatic and renal activities in rats. *J Toxicol Environ Heal Sci*. 2016; 8(2): 6–14.
24. Kakar S, Kamath PS, Burgart LJ. Sinusoidal dilatation and congestion in liver biopsy: is it always due to venous outflow impairment? *Arch Pathol Lab*. 2004; 128(8): 901–904.
25. Azab AE, Albasha MO. Hepatoprotective Effect of Some Medicinal Plants and Herbs against Hepatic Disorders Induced by Hepatotoxic Agents. *J Biotechnol Bioeng*. 2018; 2(1): 8–23.
26. Das S, Pradhan GK, Das S, Nath D, Das SK. Enhanced protective activity of nano formulated andrographolide against arsenic induced liver damage. *Chem Biol Interact*. 2015; 242 (1): 281–289.
27. Ogun M, Ozcan A, Karaman M, Merhan O, Ozen H, Kukurt A, et al. Oleuropein ameliorates arsenic induced oxidative stress in mice. *J Trace Elem Med Biol* 2016;36:1–6.
28. Kularatne S, Imbulpitiya I, Abeysekera RA, Waduge RN, Rajapakse R, Weerakoon K. Extensive haemorrhagic necrosis of liver is an unpredictable fatal complication in dengue infection: a postmortem study. *BMC Infect Dis*. 2014; 14(1): 1–10.
29. Yang D, Lv Z, Zhang H, Liu B, Jiang H, Tan X. Activation of the Nrf2 Signaling Pathway Involving KLF9 Plays a Critical Role in Allicin Resisting Against Arsenic Trioxide-Induced Hepatotoxicity in Rats. *Biol Trace element Res*. 2017; 192–200.