

ORIGINAL ARTICLE

EUGENOL AMELIORATES RHABDOMYOLYSIS-INDUCED ACUTE KIDNEY INJURY IN MICE

Nadia Saifullah¹, Rehan Ahmed Siddiqui², Zahida Memon¹, Moazzam Ali Shahid², Talat Mirza²

¹Department of Pharmacology, Ziauddin Medical College, Ziauddin University, ²Department of Research, Ziauddin University, Karachi.

ABSTRACT

Background: Acute kidney injury (AKI) is a common and dangerous consequence of rhabdomyolysis which occurs in 50% of the cases with 5-10% mortality. In recent studies, eugenol has been reported as anti-fungal, antihyperglycemic, analgesic, anti-bacterial, anti-pyretic, anti-inflammatory and anti-oxidant agent. This study aimed to investigate the protective activity of eugenol on rhabdomyolysis-induced acute kidney injury (AKI) in mice.

Methods: Male, 24 BALB/c mice were divided into 4 groups (controls, AKI, eugenol and ascorbic acid as positive control). Controls and AKI were given normal saline, Eugenol (100 mg/kg bw) and ascorbic acid (200mg/kg) were given orally eugenol and ascorbic acid respectively for four days. After water deprivation for 24 hours, all animals, except controls, were injected with glycerol (50% - 10 ml/kg body weight intra-muscularly). After another 24 hours, blood samples were collected and kidneys were dissected out for biochemical investigations (serum urea and creatinine) and histopathological examination.

Results: Serum urea and creatinine levels compared to controls were significantly elevated in AKI group ($p < 0.001$) and significantly decreased, in eugenol and ascorbic acid groups ($p < 0.001$) compared to AKI group. Histopathological examination revealed about 44% damage in the AKI group compared to the normal group ($p < 0.001$). Eugenol and ascorbic acid decreased the damage to 13% and 8% respectively compared to AKI group ($p < 0.001$). The tested compounds were found to reduce tubular cast formation.

Conclusion: Eugenol has protective effects on rhabdomyolysis-induced AKI in mice. Further studies are required for evaluation of protective role of this compound in AKI.

Keywords: Rhabdomyolysis; Acute Kidney Injury; Eugenol; Glycerol.

Corresponding Author:

Dr. Rehan Ahmed Siddiqui

Department of Research,
Ziauddin University, Karachi, Pakistan.
Email: rehan.siddiqui@zu.edu.pk

INTRODUCTION

Acute kidney injury (AKI) is represented by unexpected loss of excretory function of the kidneys with oliguria. It is a common reason for morbidity and mortality throughout the world in both the hospital and community settings. Even with advances in dialysis it continues to have a poor outcome¹. AKI is particularly common in the intensive care unit where it occurs in around 20-30% of the patients. The international society of nephrology has made an effort to reduce mortality from AKI the "0 by 2025" initiative². AKI is a common and dangerous consequence of rhabdomyolysis which occurs in 50% of the cases with 5-10% mortality³. Rhabdomyolysis

can be the result of a varied range of conditions like, trauma, poisoning, arduous exercise, burn, medications and electrolyte imbalances^{4,5}. It has an extensive variety of out-coming, from no manifestation to failure of multiple organs⁶. Rhabdomyolysis causes disruption of the sodium and calcium channels in muscle cells with resultant increase in intracellular calcium and leads to an increase in enzymes such as lactate dehydrogenase, creatinine kinase, phospholipase A2 and reactive oxygen species which damages the mitochondria and further increases intracellular calcium⁷. Rhabdomyolysis induced AKI is caused by obstruction of kidney tubular lumen by myoglobin and uric acid cast, direct myoglobin toxicity and hypovolemia and

free radical production^{8,9}.

Eugenol (1-allyl-4-hydroxy-3-methoxybenzene, C₁₀H₁₂O₂) is used as a flavouring agent in foods and is found in the essential oils of cloves, basil, nutmeg and cinnamon¹⁰. In addition, it has anti-fungal¹¹, anti-hyperglycemic^{12,13}, analgesic¹⁴, anti-bacterial¹⁵, anti-pyretic¹⁶, anti-inflammatory and anti-oxidant properties^{17,18}. Although, it has a protected role against streptozotocin¹⁹, chromium²⁰ and gentamicin-induced nephrotoxicity²¹. Its effect on rhabdomyolysis-induced AKI has not been studied up till now. The present study was conducted to determine the protective role of eugenol on rhabdomyolysis-induced nephrotoxicity.

MATERIALS AND METHODS

Male, 24 BLAB/c mice weighting 25-30gms were purchased from the animal house of International Center for Chemical and Biological Sciences, University of Karachi. The mice were kept in clean, sterile plastic cages with 12 hours light and dark cycle at room temperature (23±2°C) with free access to food and water. The animals were acclimatized with the environment and experiment before starting the experiments.

Glycerol was obtained from Daejung, Korea (D-4066-4400) and eugenol was purchased from Carl Roth, Germany (6941.1). All other chemicals used in present study were of analytical grade and purchased from reliable suppliers.

Animals were divided randomly into four groups, with six animals in each group i.e. normal control (Group 1), AKI group (Group 2), eugenol + AKI group (Group 3) and ascorbic acid + AKI group (Group 4). Animals in group 3 and 4 were pre-treated with eugenol (100 mg/kg b.w. per oral) and ascorbic acid (200 mg/kg b.w. i.p.) for four days while animals in groups 1 and 2 received normal saline. On fourth day, animals were water deprived for 24 hours followed by injection of 50% glycerol (10 ml/kg body weight i.m.) apart from animals in group 1 which was given normal saline. All animals were sacrificed 24 hours after glycerol injection, under anesthesia and samples were collected for evaluation.

Blood was collected through cardiac puncture in test tubes having no additives. The tubes were centrifuged and serum was separated for the estimation of creatinine and urea levels by spectrophotometric method using Microlab 300 (ELITech-Group).

Kidneys were dissected out, cut transversely and fixed for 4 hours in Bouin's fixative followed by washing with deionized water and placing in 70% isopropanol over night at room temperature. Ethanol in ascending concentration was used for dehydration

of the specimen. After dehydration specimen were cleared with xylene and embedded in paraffin. Tissues were cut into 5µm thick sections followed by hematoxylin and eosin (H&E) and periodic acid Schiff (PAS) staining. Microscopic examination of the tissue sections was carried out using Nikon Ts2R-FL inverted microscope and damaged area was measured using Nikon Elements D software.

Data was evaluated using SPSS version 20 using one-way ANOVA. Tukey test was used to determine the statistical significance between groups and data was presented as mean ± SD, and p value <0.05 was considered statistically significant.

RESULTS

Hematoxylin and eosin staining of the kidney is shown in Figure 1. Normal cortical structure is demonstrated in Figure 1A, B. However, obvious proximal tubular necrosis and interstitial inflammation were detected in glycerol treated animals (Figure 1C, D), along with deposition of protein cast in the loop of Henle (LH) (image not shown). On the other hand, in eugenol (100 mg/kg body weight) (Figure 1E, F) and ascorbic acid (positive control) (Figure 1G, H) pre-treated animals, notable inhibition of damage to proximal tubular cells and decreased in protein casts formation was observed. Calculation of tubular damage revealed 44% damage in diseased group in contrast to normal control (p < 0.001). Around 13% and 8% damage was observed in groups treated with eugenol and ascorbic acid (p < 0.001) (Figure 2).

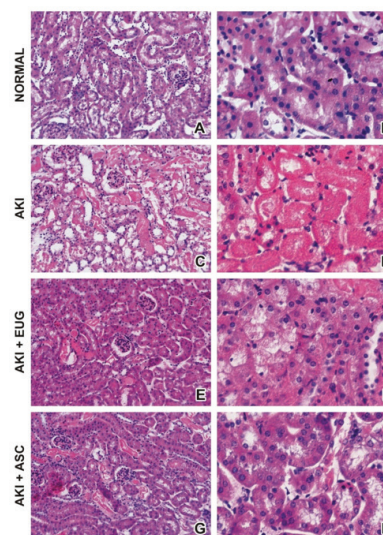


Figure 1: H&E-stained photomicrographs showing sections of kidney cortex. (200x and 600X). Normal kidney structures (A and B) AKI sections C and D showing damaged proximal tubules. E and F eugenol treated group showing notable decrease in tubular damage. G, H show sections treated with ascorbic acid which was used as a positive control.

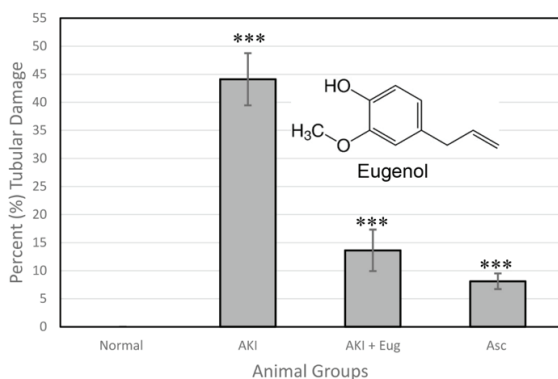


Figure 2: Damaged areas were calculated for proximal convoluted tubules of kidney sections. Sections prepared from control AKI model demonstrated marked increase in the damaged area as compared to the normal group. When the sections prepared from the treated groups were compared with the AKI control, a significant reduction in the damage of proximal convoluted tubules was observed in animals receiving ascorbic acid and eugenol (** $p < 0.001$).

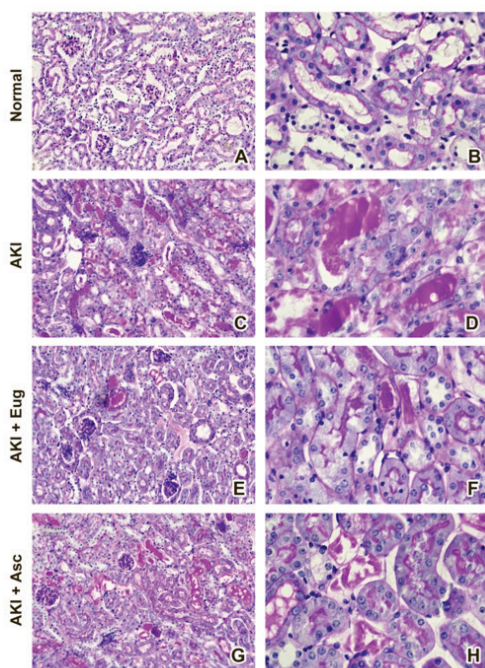


Figure 3: PAS-stained photomicrographs showing cortex of kidney sections. (200x and 600x) Sections from normal group showed intact kidney tubules and brush borders (A, B) while AKI group (C, D) exhibiting prominent damaged brush borders of proximal tubules. Note a remarkable decrease in brush border damage in E, F sections from eugenol treated group and G, H from ascorbic acid treated group.

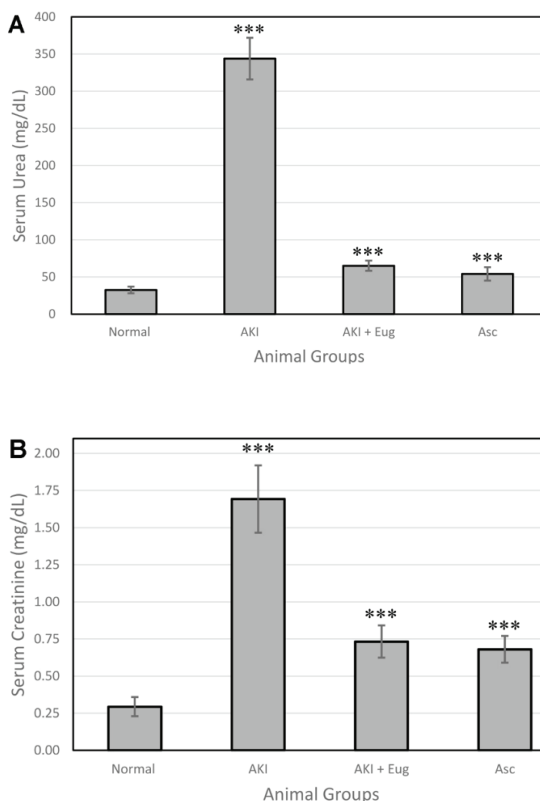


Figure 4: Serum urea (A) and creatinine (B) levels following treatment with eugenol and ascorbic acid. In comparison to the normal group, both serum urea and creatinine levels were elevated significantly in the AKI control animals. When treatment groups were compared with the AKI control animals, it was observed that eugenol and ascorbic acid significantly reversed the increase in serum urea and creatinine levels (** $p < 0.001$).

DISCUSSION

The protective effects of eugenol reflect that the test compound may play a vital role in the amelioration of kidney tubular damage and tubular cast formation. Eugenol slows down the proximal tubular cast deposition and necrosis. A study on gentamicin-induced nephrotoxicity and oxidative damage in rat kidney showed eugenol ameliorates gentamicin-induced nephrotoxicity and oxidative damage by scavenging oxygen free radicals, decreasing lipid peroxidation and improving intracellular antioxidant defense²¹. Another study demonstrated that eugenol has a protective role in the chromium-induced AKI in rats and the protection is due to its anti-inflammatory and anti-oxidant properties²².

The current study revealed the protective effects of eugenol, which is a phenolic antioxidant, on rhabdomyolysis-induced AKI in mice. The results reflect

that the test compound may play a vital role in the amelioration of kidney tubular damage and tubular cast formation. On gross examination, the kidneys of glycerol-treated animals appeared reddish and swollen with rise in their weight, compared to the normal control, which most likely resulted from the edema caused by renal tubular necrosis and inflammation and tubular cast formation due to free myoglobin and hemoglobin deposition in the kidneys. Eugenol decreased the degree of tubular damage and necrosis, as verified by histopathological examination of slides.

Most animal AKI models are developed by the administration of drugs toxic to the kidneys like cisplatin^{23,24} and gentamicin²¹ or diabetic kidney injury caused by streptozotocin²⁵. However, these models do not resemble the exact mechanisms of AKI induced by rhabdomyolysis. Glycerol damages skeletal muscles with subsequent increase of myoglobin in the blood; furthermore it also results in hemolysis with release of hemoglobin²⁶. When these proteins pass through the kidneys, catalytic iron in these proteins damages the proximal tubular cell through lipid peroxidation²⁷. This results in oxidative stress with resultant activation of inflammatory mediators in tubulointerstitial tissue. Hence, we used this animal model to determine the activity of eugenol in AKI.

In the present study pre-treatment with eugenol protected against acute kidney injury caused by glycerol which was evident through decrease in serum biomarkers like urea and creatinine with recovery of histopathological damage in renal architecture. Eugenol anti-inflammatory effects were evident by the changes in histological picture of the kidney with minor degenerative variations in lining of the tubules and not any inflammatory cell in the interstitium of the kidney of the eugenol treated group. However, further investigations are needed to explore the exact molecular mechanisms of protection by eugenol in AKI.

CONCLUSION

Our study suggests that eugenol improves rhabdomyolysis-induced acute kidney injury in mice which is evident by improvement in kidney injury biomarkers like urea and creatinine. It also ameliorates the histopathological alterations of kidney. Therefore, this compound is advocated for further investigations in the establishment of its protective role.

ACKNOWLEDGMENTS

The author thanks to Prof. Dr. Saeeda Baig to help us in the interpretation of the results and data analysis.

CONFLICT OF INTEREST

The authors declare that they have no conflict of

interest.

REFERENCES

1. Koza Y. Acute kidney injury: current concepts and new insights. *J Inj Violence Res.* 2016;8(1):58.
2. Mehta RL, Cerdá J, Burdmann EA, Tonelli M, García-García G, Jha V, Susantitaphong P, Rocco M, Vanholder R, Sever MS, Cruz D. International Society of Nephrology's 0by25 initiative for acute kidney injury (zero preventable deaths by 2025): a human rights case for nephrology. *Lancet.* 2015;385(9987):2616-43.
3. Mahbub T, Jahan F, Haque DM, Chowdhury MN. Acute kidney injury due to rhabdomyolysis. *J Armed Forces Med Col (Bangladesh).* 2015;11(1):93-5.
4. Chavez LO, Leon M, Einav S, Varon J. Beyond muscle destruction: a systematic review of rhabdomyolysis for clinical practice. *Crit Care.* 2016;20(1):135.
5. Rawson ES, Clarkson PM, Tarnopolsky MA. Perspectives on exertional rhabdomyolysis. *Sports Med.* 2017 Mar 1;47(1):33-49.
6. Safari S, Yousefifard M, Hashemi B, Baratloo A, Forouzanfar MM, Rahmati F, Motamedi M, Najafi I. The value of serum creatine kinase in predicting the risk of rhabdomyolysis-induced acute kidney injury: a systematic review and meta-analysis. *Clin Exp Neph.* 2016;20(2):153-61.
7. Kamal F, Snook L, Saikumar JH. Rhabdomyolysis-associated acute kidney injury with normal creatine phosphokinase. *Am J Med Sci.* 2018;355(1):84-7.
8. Stahl K, Rastelli E, Schoser B. A systematic review on the definition of rhabdomyolysis. *J Neuro.* 2019 Jan 7:1-6.
9. Hahn K, Kanbay M, Lanaspa MA, Johnson RJ, Ejaz AA. Serum uric acid and acute kidney injury: a mini review. *J Adv Res.* 2017;8(5):529-36.
10. Giuliani F. The Composition, Structure, Sources, and Applications of Eugenol. *ESSAI.* 2014;12(1):19.
11. Cheng SS, Liu JY, Chang EH, Chang ST. Antifungal activity of cinnamaldehyde and eugenol congeners against wood-rot fungi. *Biores Tech.* 2008;99(11):5145-9.
12. Srinivasan S, Sathish G, Jayanthi M, Muthukumar J, Muruganathan U, Ramachandran V. Ameliorating effect of eugenol on hyperglycemia by attenuating the key enzymes of glucose metabolism in streptozotocin-induced diabetic rats. *Mol Cel Biochem.* 2014;385(1-2):159-68.
13. Mnafigui K, Kaanich F, Derbali A, Hamden K, Derbali F, Slama S, Allouche N, Elfeki A. Inhibition of key enzymes related to diabetes and hypertension by Eugenol in vitro and in alloxan-induced diabetic rats. *Arch Physio Biochem.* 2013;119(5):225-33.
14. Park SH, Sim YB, Lee JK, Kim SM, Kang YJ, Jung JS, Suh HW. The analgesic effects and mechanisms of orally administered eugenol. *Arch Pharma Res.* 2011;34(3):501-7.
15. Ali SM, Khan AA, Ahmed I, Musaddiq M, Ahmed KS, Polasa H, Rao LV, Habibullah CM, Sechi LA, Ahmed N. Antimicrobial activities of Eugenol and

Cinnamaldehyde against the human gastric pathogen *Helicobacter pylori*. *Ann Clin Microb Anti*. 2005;4(1):20.

16. Feng J, Lipton JM. Eugenol: antipyretic activity in rabbits. *Neuropharmacology*. 1987;26(12):1775-8.

17. Yogalakshmi B, Viswanathan P, Anuradha CV. Investigation of antioxidant, anti-inflammatory and DNA-protective properties of eugenol in thioacetamide-induced liver injury in rats. *Toxicol*. 2010;268(3):204-12.

18. Daniel AN, Sartoretto SM, Schmidt G, Caparroz-Assef SM, Bersani-Amado CA, Cuman RK. Anti-inflammatory and antinociceptive activities A of eugenol essential oil in experimental animal models. *Rev Bras Farmacogn*. 2009;19(1B):212-7.

19. Garud MS, Kulkarni YA. Eugenol ameliorates renal damage in streptozotocin-induced diabetic rats. *Flavour Frag J*. 2017;32(1):54-62.

20. Barhoma RA. The role of eugenol in the prevention of chromium-induced acute kidney injury in male albino rats. *Alexandria J Med*. 2018;54(4):711-5.

21. Said MM. The protective effect of eugenol

against gentamicin-induced nephrotoxicity and oxidative damage in rat kidney. *Fund Clin Pharmacol*. 2011;25(6):708-16.

22. Barhoma RA. The role of eugenol in the prevention of chromium-induced acute kidney injury in male albino rats. *Alexandria J Med*. 2018;54(4):711-5.

23. Ozkok A, Edelstein CL. Pathophysiology of cisplatin-induced acute kidney injury. *Bio Med Res Int*. 2014;2014.

24. Xu Y, Ma H, Shao J, Wu J, Zhou L, Zhang Z, Wang Y, Huang Z, Ren J, Liu S, Chen X. A role for tubular necrosis in cisplatin-induced AKI. *J Am Soc Nephrol*. 2015;26(11):2647-58.

25. Garud MS, Kulkarni YA. Eugenol ameliorates renal damage in streptozotocin-induced diabetic rats. *Flavour Frag J*. 2017;32(1):54-62.

26. Holt S, Moore K. Pathogenesis of renal failure in rhabdomyolysis: the role of myoglobin. *Nephron Exp Nephrol*. 2000;8(2):72-6.

27. Zhang MH. Rhabdomyolysis and its pathogenesis. *W J Emerg Med*. 2012;3(1):11.

