

ORIGINAL ARTICLE

LOSS OF CORRECTION BY SEGMENTAL PEDICLE SCREWS COMPARED TO HYBRID FIXATION IN ADOLESCENT IDIOPATHIC SCOLIOSIS

Mustafa Pervez¹, Imtiaz A. Hashmi¹, Sohail Rafi¹, Idrees Shah¹, Aqeel A. Memon¹

¹Department Of Orthopaedics, Ziauddin University Hospital, Karachi, Pakistan.

ABSTRACT

Objective: This study was conducted to collate and compare a 1 year post-surgical radiographic outcome of posterior spinal instrumentation and correction in the coronal plane with the use of pedicle screws against hybrid fixation in patients with adolescent idiopathic scoliosis.

Method: Cross-sectional study involving 34 patients who underwent scoliosis correction. The variables were measured pre-operatively, immediately post surgery and in two 6 monthly OPD follow-ups. Data analysis of data was conducted in SPSS version 20.

Results: Average major curve was corrected from $58.0 \pm 13.0^\circ$ pre-op to $16.0 \pm 9.0^\circ$ using pedicle screws fixation and increased to $18.4 \pm 8.6^\circ$ at first year follow-up and using hybrid construct, the normal major curve was corrected from $62.0 \pm 13.0^\circ$ pre-op to $18.0 \pm 8.0^\circ$ and increased to $22 \pm 9^\circ$. By 1 year of follow-up, differences were apparent between the two groups considering the curvature in the coronal plane.

Conclusion: Cobbs angles between pre-operative and post operative correction and 1-year radiographic follow-up evaluation was better in the instrumentation fixation using pedicle screws compared to hybrid instrumentation. Using pedicle screws there was a correction loss of 12.5% as compared to the 16.6% using hybrid fixation Pedicle screw instrumentation. Pedicle screw fixation also has the advantage of allowing three dimensional correction of deformity.

KEYWORDS: Adolescent, Scoliosis, Pedicle Screws

Corresponding Author

Dr. Mustafa Pervez (Resident M.S Ortho)

Department of Orthopaedics,
Ziauddin University Hospital, Block 4 Clifton, Karachi
Email: mustufa_pervez@hotmail.com

INTRODUCTION

Scoliosis is the lateral deviation of the vertebrae in the coronal plane. In its mild form, it may only cause shape changes in the trunk but severe forms can lead to neurological, cardiac and pulmonary changes as well.¹

The Scoliosis Research Society classifies idiopathic scoliosis according to the age of onset. From birth to three years of age it is termed Infantile Scoliosis; between ages 4-10 it is called Juvenile scoliosis and between age 10 and upwards it is termed Adoles-

cent scoliosis, which is the most common form.²

Segmental instrumentation was introduced by Luque in 1982 combining rods with sub laminar wires and later the segmental hook rod system was developed by Cotrel-Dubousset.^{3,4} Pedicle screws instrumentation have become the main stay of fixation method to correct deformities of the spine but still problems such as nerve root injury are associated with screw placements.⁵ As a result the optimal treatment choice is still debated. We presume that the all-screw method provides a better three dimensional corrections and stability.⁶

METHODS

This cross-sectional study was conducted at Dr. Ziauddin Hospital Clifton Karachi from January 2013 to December 2016 assessing a number of variables such as age, sex and pre-operative, immediate post operative Cobb's angle and the Cobb's angle at two 6 monthly follow-ups. Antero-posterior and lateral X-rays of the whole spine were performed in standing position at the periods.³⁴ patients with adolescent idiopathic scoliosis (23 females, 11 males) were evaluated. Patients with congenital or neuromuscular scoliosis were excluded and so were those undergoing revision surgery. The maximum follow-up was 1 year. The mean patient age was 16.5 ± 5 years. Lenke's classification system was used to grade the curve. Fixation points were decided pre-surgery on radiographs and posterior midline approach was used in all the cases. All the patients were instrumented with pedicle screws, hooks, rods and transverse bars. Decortication of the posterior spine and the capsule were performed to favor bone fusion. Wake-up test was performed in all instances. The data was analyzed in SPSS version 20 with a P value of < 0.05 .

RESULTS

From 2013 to 2016, 34 patients were reviewed with imaging exams for adolescent idiopathic scoliosis. The study included 11 males and 23 female patients. 14 patients underwent correction using Hybrid Fixation and the rest were operated using the segmental fixation technique. The mean Cobb angle showed no statistical difference between the two genders and no neurological complications were observed and neither were implant failures during the follow-up duration. Superficial infection was seen in only one case and was resolved by medical treatment.

The average major curve correction from $58.0 \pm 13.0^\circ$ Pre-op to $16.0 \pm 9.0^\circ$ was observed using pedicle screw fixation and increased to $18.4 \pm 8.6^\circ$ at one year follow-up. This showed a 71% correction rate and loss of $\pm 2^\circ$. Using hybrid construct, the average curve correction from $62.0 \pm 13.0^\circ$ Pre-op to $18.0 \pm 8.0^\circ$ was observed and increased to $22 \pm 9^\circ$ at first year follow-up.

Using pedicle screws there was a correction loss of 12.5% as compared to the 16.6% using hybrid fixation. By 1 year follow-up the differences were obvious between the two groups.

Table 1: Gender based distribution in the PSF and HI groups.

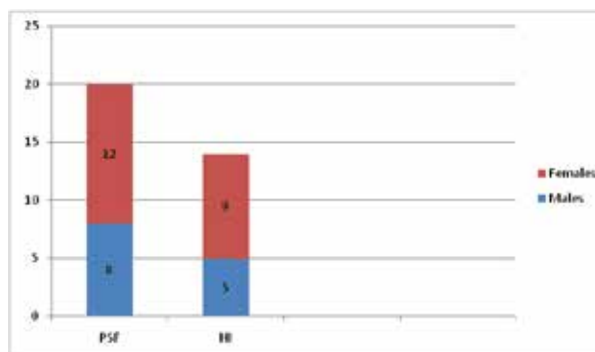


Table 2: Cobb angles – pre, post and at 1 year follow-up.

	Pedicle Screws	Hybrid Fixation
Average Pre-operative Cobb's	58.0 ± 13.0	62.0 ± 13.0
Average Post-operative Cobb's	$16.0 \pm 9.0^\circ$	$18.0 \pm 8.0^\circ$
Cobb's in 1 year	$18.4 \pm 8.6^\circ$	$21 \pm 9^\circ$
% Loss in 1 year	12.5%	16.6%

DISCUSSION

Albeit some contention exists, the all-screw build has increased overall success in the treatment of idiopathic scoliosis in this decade. This mirrors the agreement that all pedicle screw instrumentation accomplishes better three dimensional correction and less loss when compared to hybrid instrumentation.^{7,8} An immediate examination between these builds uncovered a predominant correction in pedicle screws method in 58 AIS patients (70% vs 56%) which also acknowledges a past report utilizing Moss Miami hybrid fixation in 61 AIS patients having a rectification rate of 56% in the thoracic curves.⁹

Two studies published by Kim et al in 2004 compared the results of PS and hook instrumentation and published another one in 2004 comparing the results of pedicle screws instrumentation with hybrid instrumentation. In the former study they found the pedicle screw instrumentation to be superior because of better correction rate and less loss of correction in coronal and sagittal plans. Blood loss and operative time did not differ between the two

groups. The latter study concluded that the correction rate and AVT were better in the Ps group, global and sagittal balance and blood loss were still similar.¹⁰

The PSF system is considered biomechanically advantageous because the pedicle is the hardest part of the vertebral body and is used as an anchor in this system and because of this advantage it allows improved correction of the deformity with preservation of the motion segments by reducing number of fused levels.¹¹

One of the limitations of the present study is that the

patients did not belong to a single Lenke group, which made standardization difficult. However, in both the pedicle screw fixation and hybrid instrumentation groups, there were patients from different Lenke groups.¹²

Correction pedicle screw fixation is a safe and effective surgical method. Compared to Hybrid instrumentation, these patients displayed significantly improved correction of the major curve. Our study was consistent with previous studies in which pedicle screw fixation was found to be superior to hybrid instrumentation in the treatment of adolescent scoliosis.^{13,14}

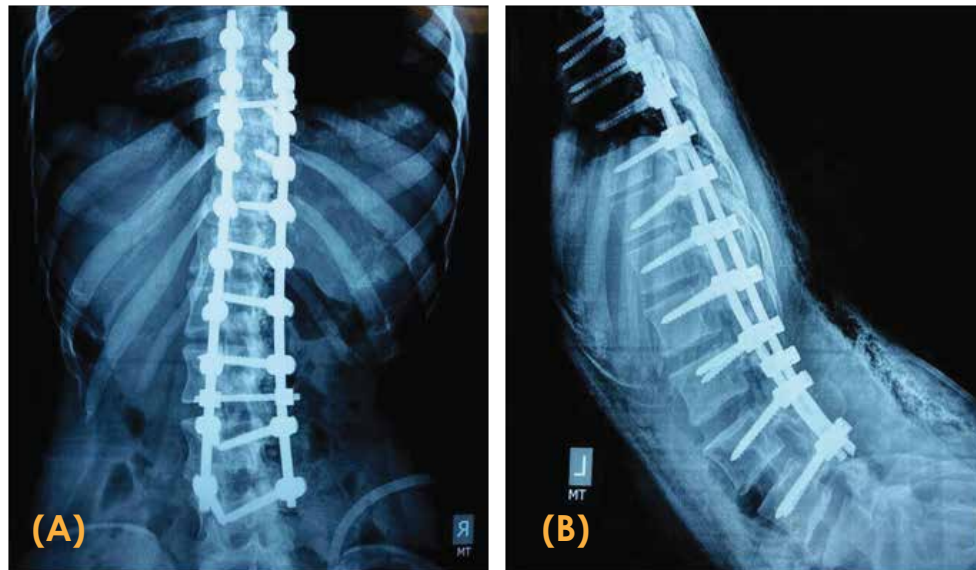


Figure 1: Post-operative x-rays of a female patient aged 13, with AIS having a Cobb's angle of 62 degrees corrected using pedicle screws segmental fixation. (A) Antero-Posterior View (B) Lateral View

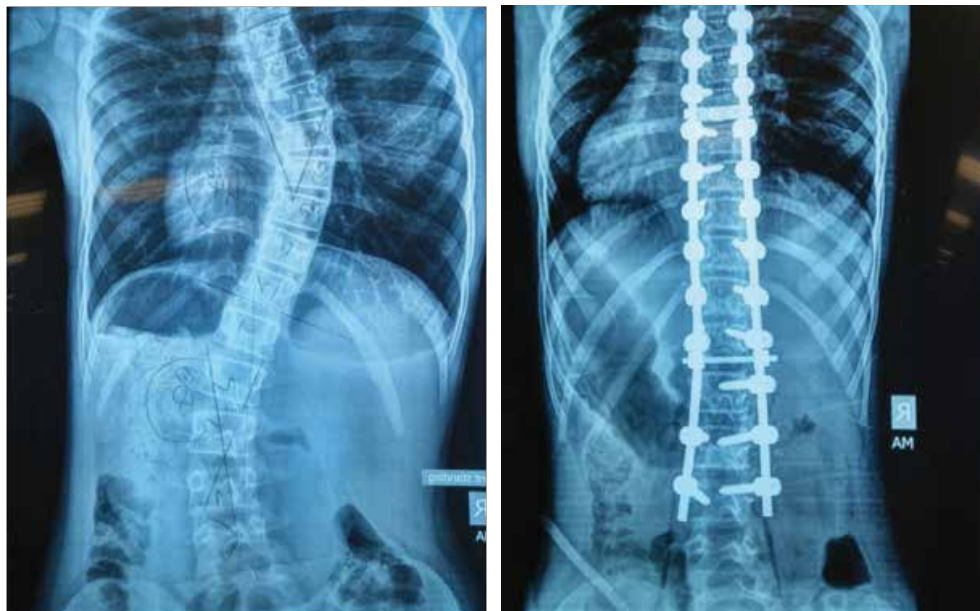


Figure 2: Comparative x-rays of a 10 year old female patient with AIS. Pre-operative Cobb's angle of 44 degrees. (A) Pre-operative x-rays (B) Post-operative x-rays.

CONCLUSION

Cobbs angles between pre-operative and post operative correction and 1-year radiographic follow-up evaluation was better in the instrumentation fixation using pedicle screws compared to hybrid instrumentation. Using pedicle screws there was a correction loss of 12.5% as compared to the 16.6% using hybrid fixation. Pedicle screw instrumentation. Pedicle screw fixation also has the advantage of allowing three dimensional correction of deformity.

REFERENCES

1. Asghar J, Samdani AF, Pahys JM, D'andrea LP, Guille JT, Clements DH, et al. Computed tomography evaluation of rotation correction in adolescent idiopathic scoliosis: a comparison of an all pedicle screw construct versus a hookrod system. *Spine (Phila Pa 1976)* 2016;34:804-7.
2. Tsirikos, A. I., Mataliotakis, G., & Bounakis, N. (2017). Posterior spinal fusion for adolescent idiopathic scoliosis using a convex pedicle screw technique. *Bone Joint J*, 99-B(8), 1080-1087. Accessed September 12, 2017
3. Rafi S, Munshi N, Abbas A, Shaikh RH, Hashmi I. Comparative analysis of pedicle screw versus hybrid instrumentation in adolescent idiopathic scoliosis surgery. *Journal of Neurosciences in Rural Practice*.2016;7(4):550-553.doi:10.4103/0976-3147.185510.
4. Pedicle screw versus hybrid instrumentation in adolescent idiopathic scoliosis: A systematic review and meta-analysis with emphasis on complications and reoperations Luo, Ming MMed; Li, Ning MD; Shen, MingkuiMMed; Xia, Lei MD* Section Editor(s): Schaller., Bernhard *Medicine*: July 2017 - Volume 96 - Issue 27 - p e7337 10.1097/MD.0000000000007337
5. Crawford AH, Lykissas MG, Gao X, Eismann E, Anadio J. All-pedicle screw versus hybrid instrumentation in adolescent idiopathic scoliosis surgery: a comparative radiographical study with a minimum 2-Year follow-up. *Spine (Phila Pa 1976)* 2013;38:1199-208.
6. Jaquith BP, Chase A, Flinn P, Sawyer JR, Warner WC, Freeman BL, et al. Screws versus hooks: implant cost and deformity correction in adolescent idiopathic scoliosis. *J Child Orthop* 2014;6:137-43.
7. Suk S-I. Pedicle Screw Instrumentation for Adolescent Idiopathic Scoliosis: The Insertion Technique, the Fusion Levels and Direct Vertebral Rotation. *Clinics in Orthopedic Surgery*. 2011;3(2):89-100. doi:10.4055/cios.2011.3.2.89.
8. Suk SI, Lee SM, Chung ER, Kim JH, Kim SS: Selective thoracic fusion with segmental pedicle screw fixation in the treatment of thoracic idiopathic scoliosis: more than 5-year follow-up. *Spine* 2015, 30(14):1602-1609.
9. Basu S, Rathinavelu S, Baid P. Posterior scoliosis correction for adolescent idiopathic scoliosis using side-opening pedicle screw-rod system utilizing the axial translation technique. *Indian Journal of Orthopaedics*. 2010;44(1):42-49. doi:10.4103/0019-5413.58605.
10. Suk SI, Kim WJ, Lee SM, Kim JH, Chung ER: Thoracic pedicle screw fixation in spinal deformities: are they really safe? *Spine* 2001, 26(18):2049-2057.
11. McCormick J, Aebi M, Toby D, Arlet V. Pedicle screw instrumentation and spinal deformities: have we gone too far? *European Spine Journal*. 2013;22(-Suppl 2):216-224. doi:10.1007/s00586-012-2300-5.
12. Lehman RA Jr, Lenke LG, Keeler KA, Kim YJ, Buchowski JM, Cheh G, Kuhns CA, Bridwell KH: Operative treatment of adolescent idiopathic scoliosis with posterior pedicle screw-only constructs: minimum threeyear follow-up of one hundred fourteen cases. *Spine* 2012, 33(14):1598-1604.
13. Gotfryd AO, Franzin FJ, Raucci G, Neto NJC, Poletto PR. Tratamentocirúrgico da escoliose idiopática do adolescenteutilizandoparafusospediculares: Análise dos resultadosclínicoseradiográficos. *Coluna/Columna*.2011;10(2) :91-6.
14. Pratali RR, Neto MIR, Veiga IG, Pascoaline W, Cavali PTM, Santos MAM, et al. Parafusopedicular: método paracorreção da deformidadena escoliose idiopática do adolescente. *Coluna/Columna*. 2010;9(3):271-276.
15. Yuan S, Qiu Y, Zhu F, Wang B, Yu Y, Zhu ZZ, et al. A comparative study on the surgical outcomes of spinal fusion in adolescent idiopathic scoliosis patients with or without triradiate cartilages closed. *ZhonghuaWaiKeZaZhi*. 2011;49(5):414-8.
16. Lehman RA Jr, Lenke LG, Keeler KA, Kim YJ, Buchowski JM, Cheh G, et al. Operative treatment of adolescent idiopathic scoliosis with posterior pedicle screw-only constructs: minimum threeyear follow-up of one hundred fourteen cases. *Spine (Phila Pa 1976)*. 2008;33(14):1598-604.
17. Cui G, Watanabe K, Nishiwaki Y, Hosogane N, Tsuji T, Ishii K, et al . Loss of apical vertebral derotation in adolescent idiopathic scoliosis: 2-year follow-up using multi-planar reconstruction computed tomography. *Eur Spine J*. 2012;21(6):1111-20.
18. Rodrigues LMR, Yonezaki AM, Ueno FH, Nicolau RJ, Abreu LC, Filho EVS, et al. Escoliose idiopática do adolescente: análise do grau de correção obtido com o uso de parafusospediculares. *Arq Bras CiêncSaúde*. 2009;35(1):1-11.
19. Lonstein JE, Bjorklund S, Wanninger MH, Nelson RP. Voluntary school screening for scoliosis in Minnesota. *J Bone Joint Surg Am*. 1982;64(4):481-8.
20. Aaro S, Dahlborn M (1981) Estimation of vertebral rotation and the spinal and rib cage deformity in scoliosis by computer tomography. *Spine* 6:460-467
21. Halm H, Niemeyer T, Link T, Liljenqvist U (2000) Segmental pedicle screw instrumentation in idiopathic thoracolumbar and lumbar scoliosis. *Eur Spine J* 9:191-197

22. Kim YJ, Lenke LG, Cho SK, Bridwell KH, Sides B, Blanke K (2004) Comparative analysis of pedicle screw versus hook instrumentation in posterior spinal fusion of adolescent idiopathic scoliosis. *Spine* 29:2040-2048
23. Lenke LG, Kim Y, Rinella A (2002) Treatment of spinal deformity utilizing thoracic pedicle screws. *Seminars Spine Surg* 14:66-87
24. Leung JP, Lam TP, Ng BK, Cheng JC (2002) Posterior ISOLA segmental spinal system in the treatment of scoliosis. *J PediatrOrthop* 22:296-301
25. Lagrone MO, Bradford DS, Moe JH, Lonstein JE, Winter RB, Ogilvie JW: Treatment of symptomatic flatback after spinal fusion. *J Bone Joint Surg Br* 1988, 70(4):569-580.
26. Kim YJ, Lenke LG, Cho SK, Bridwell KH, Sides B, Blanke K: Comparative analysis of pedicle screw versus hook instrumentation in posterior spinal fusion of adolescent idiopathic scoliosis. *Spine* 2004, 29(18):2040-2048.
27. Lai SM, Asher M, Burton D: Estimating SRS-22 quality of life measures with SF-36: application in idiopathic scoliosis. *Spine* 2006, 31(4):473-478.
28. Schwab F, Dubey A, Pagala M, Gamez L, Farcy JP: Adult scoliosis: a health assessment analysis by SF-36. *Spine* 2003, 28(6):602-606.
29. Modi HN, Suh SW, Fernandez H, Yang JH, Song H-R. Accuracy and safety of pedicle screw placement in neuromuscular scoliosis with free-hand technique. *European Spine Journal*. 2008;17(12):1686-1696.doi:10.1007/s00586-008-0795-6.

