

PERSISTENT PUPILLARY MEMBRANE

Muhammad Sharjeel

Department of Ophthalmology, Gomal Medical College, D.I.Khan, Pakistan

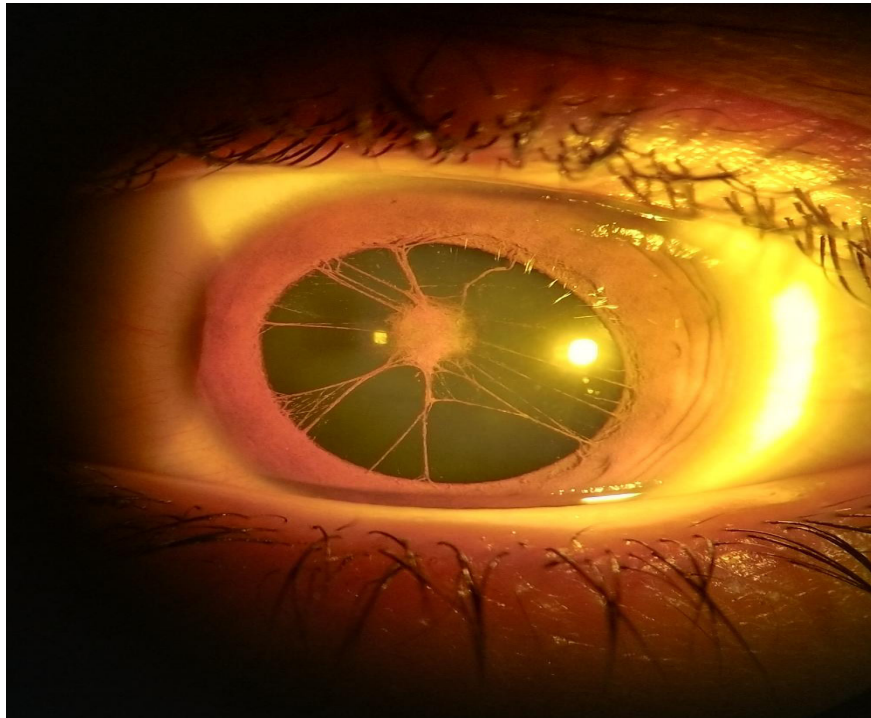


Figure: Dilated pupil showing persistent pupillary membrane.

PERSISTENT PUPILLARY MEMBRANE

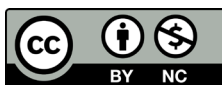
A 12 years old girl from D.I.Khan city, Pakistan presented with diminished vision. On examination her vision was 6/60 in both eyes, not improving with glasses. The intra-ocular pressure was 15 mmHg in both eyes. Both the corneas were clear and pupils were round, and reactive to light. There was pupillary membrane covering the entire pupil in undilated state. After dilation, we took the picture shown. The persistent pupillary membrane is usually an innocuous finding diagnosed on routine slit-lamp examination but in this case, it was adherent to the anterior lens capsule causing anterior capsular cataract, affecting the visual acuity.

This article may be cited as: Sharjeel M. persistent pupillary membrane [Images in clinical medicine]. Gomal J Med Sci 2018 Jul-Sep; 16 (3):88. <https://doi.org/10.46903/gjms/16.03.1932>

Corresponding Author:

Dr. Muhammad Sharjeel
Senior Registrar, Department of Ophthalmology
Gomal Medical College, D.I.Khan, Pakistan
E-mail: dr.sharjeel@gmail.com

CONFLICT OF INTEREST
Authors declare no conflict of interest.
GRANT SUPPORT AND FINANCIAL DISCLOSURE
None declared.



Copyright © 2020 Muhammad Sharjeel. This is an Open Access article distributed under the terms of the Creative Commons Attribution-Non Commercial 4.0 International License, which permits unrestricted use, distribution & reproduction in any medium provided that original work is cited properly.