

COLLODION BABY

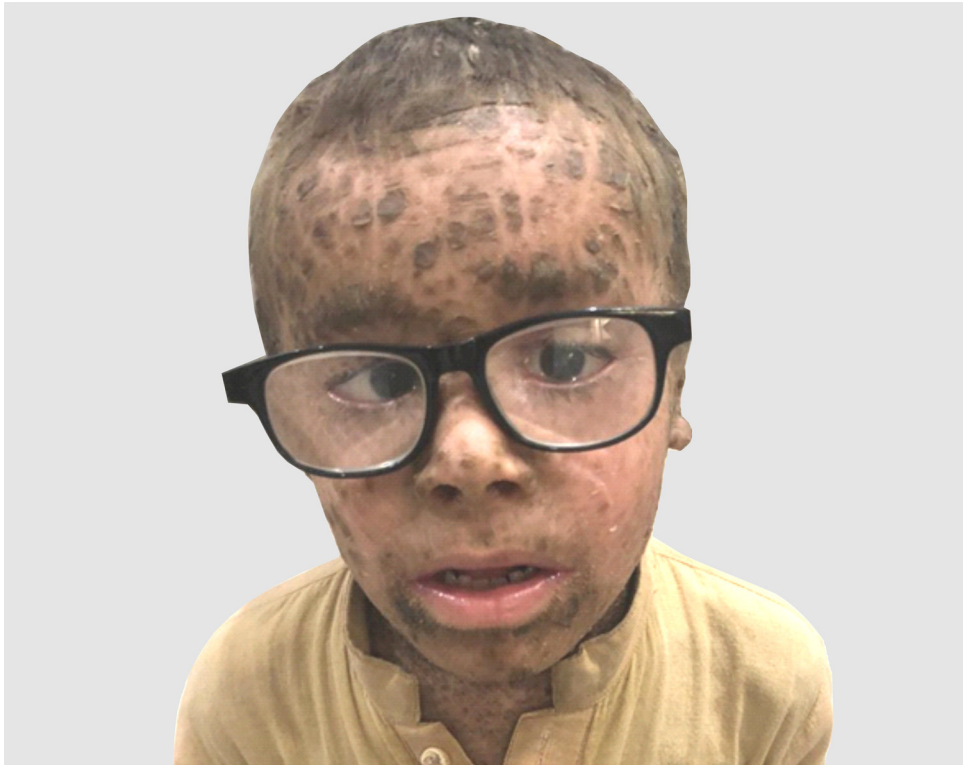

Figure: Seven years old collodion baby with hypermetropic esotropia

This 7 years old male child is a case of collodion baby who goes to school. He is having high hypermetropia

with esotropia and bilateral lower lid ectropions. He has got a younger sister of four years age with similar problem whereas another brother is quite normal. His parents are first cousins to each other, showing genetic predilection of this un-common congenital disorder. He needs regular skin massage with Vaseline thrice a day. Such patients are more prone to dehydration and infections.

This article may be cited as: Ahmad I. Collodion baby [Images in clinical medicine]. Gomal J Med Sci 2019 Jan-Mar;17(1):23. <https://doi.org/10.46903/gjms/17.01.2012>

Corresponding Author:

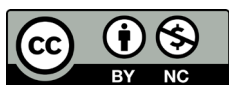
Professor Iftikhar Ahmad
Department of Community Medicine
Gomal Medical College, D.I.Khan, Pakistan
E-mail: iftikharahmadgandapur66@gmail.com

CONFLICT OF INTEREST

Authors declare no conflict of interest.

GRANT SUPPORT AND FINANCIAL DISCLOSURE

None declared.



Copyright © 2020 Iftikhar Ahmad. This is an Open Access article distributed under the terms of the Creative Commons Attribution-Non Commercial 4.0 International License, which permits unrestricted use, distribution & reproduction in any medium provided that original work is cited properly.