

# MANAGEMENT OF HIGH FISTULA IN ANO WITH CUTTING SETON

Akhtar Munir, Sheikh Qais Falah

Department of Surgery, Gomal Medical College, D.I.Khan, Pakistan

## ABSTRACT

**Background:** Management of high fistula-in-ano is a surgical challenge. Fistulotomy cannot be done in such cases due to the risk of sphincter damage and subsequent fecal incontinence. The aim of this study was to determine the rate of faecal incontinence and recurrence in patients with high fistula-in-ano treated with polypropylene (prolene-1) as cutting seton.

**Material & Methods:** This was a descriptive cross-sections study of 30 consecutive patients of high fistula in ano treated with cutting seton at Mufti Mehmood Memorial Teaching Hospital, D.I.Khan from 1-4-2011 to 31-3-2014. Follow-up was made for at least 6 months to record the fistula recurrence, anal incontinence and duration of complete wound healing.

**Results:** The study involved 30 patients of mean age 40 years (range 20 to 66 years). Complete healing occurred in all the patients (100%) within 3 months. Recurrent fistula was noted in one (3.3%) patient at 5 months while none developed incontinence.

**Conclusion:** Treatment of high fistula-in-ano with cutting seton is associated with low complication rate. It can therefore be recommended as the standard treatment for high fistula-in-ano.

**Key Words:** Fistula in ano; Fistula; Polypropylene; Recurrence.

**This article may be cited as:** Munir A, Falah SQ. Management of high fistula in ano with cutting seton. Gomal J Med Sci 2014; 12: 210-2.

---

## INTRODUCTION

Management of high fistula-in-ano is a surgical challenge. Fistulotomy cannot be done in such cases due to risk of sphincter damage and subsequent fecal incontinence.<sup>1-3</sup> Several alternative treatment strategies have been practiced in order to preserve the sphincter mechanism, including cutting setons, draining setons,<sup>3-8</sup> rectal mucosal or full thickness advancement flaps,<sup>9-11</sup> rerouting,<sup>12</sup> two-stage seton fistulotomy,<sup>13</sup> anal fistula plug,<sup>14-16</sup> ligation of the intersphincteric fistula tract (LIFT),<sup>17,18</sup> fistulotomy with reconstruction of the sphincter mechanism<sup>19</sup> or fibrin glue.<sup>20</sup> Whatever the type and the extent of fistula are, the principles of anal fistula surgery are to get rid of the fistula, prevent recurrence and preserve sphincter function.

The oldest and theoretically the simplest technique is to use seton.<sup>4</sup> Seton is any string like material which when tied through the fistula tract causes

an inflammatory reaction which stimulates fibrosis that fixes and prevents retraction of the sphincter continuity when it is divided. In this way, it maintains sphincter continuity during cutting process.<sup>21,22</sup> Secondly, it slowly drains and divides the fistulous tract resulting in eradication of fistula and healing of the wound<sup>23</sup>. Different types of setons are used for this purpose like silastic tube, silk, linen, braided silk, rubber band, braided polyester, vascular loop, polypropylene, nylon, cable tie and so forth.<sup>21</sup>

The aim of this study was to determine the rate of faecal incontinence and recurrence in patients with high fistula-in-ano treated with polypropylene (prolene-1) as cutting seton.

## MATERIAL AND METHODS

This descriptive cross-sections study was carried out in Mufti Mehmood Memorial Teaching Hospital, D. I. Khan, over a period of 3 years from 1-4-2011 to 30-3-2014.

In all cases of perianal fistula, a detailed history was taken and complete clinical examination was made. Patients with high fistula-in-ano were included in the study. Diagnosis of type of fistula was made on per-operative findings. Patients with fistulae second-

---

### Corresponding Author:

Dr. Akhtar Munir

Associate Professor

Department of Surgery, Gomal Medical College

D.I.Khan, Pakistan

E-mail: surgakhtarmunir@yahoo.com

ary to inflammatory bowel disease, past or present malignancies and trauma were excluded from the study. Patients with concomitant anorectal problems like hemorrhoids were also excluded from the study.

Operations were performed in spinal or general anesthesia with patients in lithotomy position. The internal opening was identified by injecting hydrogen peroxide through the external opening. Fistula tract was probed gently with flexible metal probe. Polypropylene (Prolene-1) was passed through the tract and was tightened firmly after cutting the overlying skin and subcutaneous tissue and excision of external opening of fistula tract. Patients were asked to come for follow-up fortnightly. Tightening of seton was done after one month and then at 2 months follow-up, it was removed by cutting remaining tissue in the loop of seton. By 2 month time, it was found that seton almost cuts completely through the sphincter and fistula. Postoperatively, wound healing, anal continence and recurrence were assessed for at least 6 months.

## RESULTS

During the study period, 30 consecutive patients fulfilling the selection criteria were treated with cutting seton. Out of these, 24 (75%) were males and 6 (25%) females. Age ranged from 20 to 66 years (mean 40 years). Patients were followed-up for at least 6 months (range 6–48, median 22 months). Twenty-five (83.3%) patients had high trans-sphincteric and 5 (16.6%) had supra-sphincteric fistula. Six (20%) patients had history of previous surgery on fistula-in-ano, 8 (26%) patients had past history of incision and drainage for perianal abscess, 5 (16.6%) had multiple external openings while 25 (83.3%) had single external opening. Eighteen (60%) patients had posterior while twelve (40%) had anterior fistulae. Complete healing was achieved in 25 patients at two and a half months and in all patients (100%) at three months.

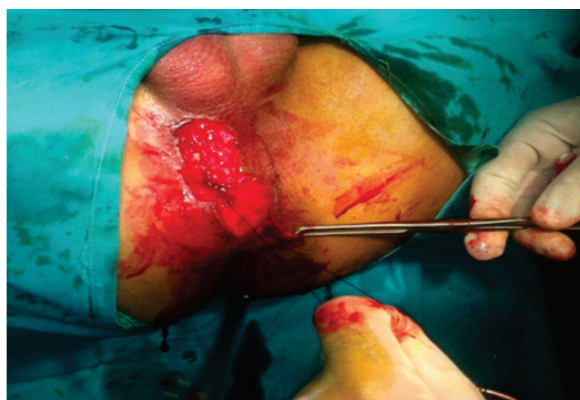


Figure 1: Prolene-1 being applied in a case of high anterior fistula-in-ano.

Recurrent fistula appeared in one (3.3%) patient, five months after seton placement. No case of faecal incontinence was noted.

## DISCUSSION

Prolene-1 has been used in this study as cutting seton. This is durable, non-toxic/non-allergic and is easily available in sterile packing at a reasonable price. There are several other materials used as seton as mentioned in introduction, but whatever the material is, recurrence and incontinence rate is mainly dependent on expertise and judgement of the surgeon.<sup>21</sup> In this study, we found 0% incontinence and 3.3% recurrence rate in 30 patients treated with cutting seton for high anal fistulas. Different studies have shown different results with recurrence rate ranging from 0 to 18%, while long term incontinence rates can exceed 30%.<sup>24</sup> The incontinence reported in different studies is usually of minor nature. The 0% incontinence rate in our study can be attributed to meticulous surgical technique whereby sphincter remains intact. Low recurrence rate in our study is due to proper identification of internal opening and the extensions of fistula tract.

In our study, we were able to identify the internal opening in all the patients without radiological investigations. MRI is a useful aid in complex fistulas to find the fistula tract and its extensions, however, it is a costly investigation and most of the patients operated in our setup are poor and can't afford it.

Loose seton or draining seton is another treatment of high fistula in ano, but requires second procedure (fistulotomy)<sup>22,23</sup> and duration of treatment is longer when compared with cutting seton.<sup>23</sup> Other techniques of treatment are reported including 'fibrin glue' and 'Ligation of intersphincteric fistula tract (LIFT)'. Fibrin glue is costly, not widely available and doesn't offer any advantage over other techniques in terms of recurrence or incontinence following the procedure.<sup>25</sup> Earlier experience of LIFT is good, however, it has a steep learning curve.<sup>26</sup>

## CONCLUSION

Prolene-1 used as cutting seton is a safe and low morbidity option for the treatment of high fistula-in-ano. It can therefore be recommended as the standard treatment for high fistula-in-ano.

Surgeon should be able to identify internal opening and extensions of the fistula tract to prevent recurrence while incontinence can be avoided by doing careful dissection so that the sphincter remains safe.

## REFERENCES

1. Lunniss PJ, Kamm MA. Factors affecting continence after surgery for anal fistula. *Br J Surg* 1994; 81:1382-5.

2. Garcia-Aguilar J, Belmonte C, Wong DW, Goldberg SM, Madoff RD. Anal Fistula surgery. Factors associated with recurrence and incontinence. *Dis Colon Rectum* 1996; 39:723-9.
3. Bokhari S, Lindsey I. Incontinence following sphincter division for treatment of anal fistula. *Colorectal Dis* 2010; 12:35-9.
4. McCourtney JS, Finlay IG. Setons in the surgical management of fistula in ano. *Br J Surg* 1995; 82:448-52.
5. Van Tets WF, Kuijpers JH. Seton treatment of perianal fistula with high anal or rectal opening. *Br J Surg* 1995; 82:895-7.
6. Montes BB, Oktemer S, Tezkaner T, Azili C, Leventoglu S, Oguz M. Elastic one-stage cutting seton for the treatment of high anal fistulas : preliminary results. *Tech Coloproctol* 2004; 8:159-62.
7. Buchanan G, Owen H, Torkington J, Luniss P, Nicholls RJ, Cohen R. Long-term outcome following loose-seton technique for external sphincter preservation in complex anal fistula. *Br J Surg* 2004; 91:476-80.
8. Schouten W, Gosselink M. Invited comment long-term outcome following loose-seton technique for external sphincter preservation in complex anal fistula. *Tech Coloproctol* 2005; 9:79.
9. Abbas M, Lemus-Rangel R, Hamadami A. Long-term outcome of endorectal advancement flap complex anorectal fistulae. *Am Surg* 2008; 74:921-4.
10. Lewis P, Bartolo DC. Treatment of trans-sphincteric fistulae by full thickness anorectal advancement flaps. *Br J Surg* 1990; 77:1187-9.
11. Khafagy W, Omar W, El Nakeeb A, Fouda E, Yousef M, Farid M. Treatment of anal fistulas by partial rectal wall advancement flap or mucosal advancement flap: a prospective randomized study. *Int J Surg* 2010; 8:321-5.
12. Mann CV, Clifton MA. Rerouting of the track for the treatment of high anal and anorectal fistulae. *Br J Surg* 1985; 72:134-7.
13. Garcia-Aguilar J, Belmonte C, Wong DW, Goldberg SM, Madoff RD. Cutting seton versus two-stage seton fistulotomy in the surgical management of high anal fistula. *Br J Surg* 1998; 85:243-5.
14. Safar B, Jobanputra S, Sands D, Weiss EG, Nogueras JJ, Wexner SD. Anal fistula plug: initial experience and outcomes. *Dis Colon Rectum* 2009; 52:248-52.
15. Owen G, Keshava A, Stewart P et al. Plugs unplugged. Anal fistula plug: the Concord experience. *ANZ J Surg* 2010; 80:341-3.
16. Ellis CN, Rostas JW, Greiner FG. Long-term outcomes with the use of bioprosthetic plugs for the management of complex anal fistulas. *Dis Colon Rectum* 2010; 53:798-802.
17. Rojanasakul A, Pattanaarun J, Sahakitrungruang C, Tantiphlachiva K. Total anal sphincter saving technique for fistula-in-ano: the ligation of intersphincteric fistula tract. *J Med Assoc Thai* 2007; 90:581-6.
18. Bleier JI, Moloo H, Goldberg SM. Ligation of the intersphincteric fistula tract: an effective new technique for complex fistulas. *Dis Colon Rectum* 2010; 53:43-6.
19. Hyman N, O'Brien S, Osler T. Outcomes after fistulotomy: results of a prospective, multicenter regional study. *Dis Colon Rectum* 2009; 52:2022- 7.
20. Sentovic SM. Fibrin Glue for anal fistulas. *Dis Colon Rectum* 2003; 46: 498-502.
21. Ritchie RD, Sackier JM, Hodde JP. Incontinence rates after cutting seton treatment for anal fistula. *Colorectal Dis* 2009; 11:564-71.
22. Memon AA, Murtaza G, Azami R, Zafar H, Chawla T, Laghari AA. Treatment of complex fistula in ano with cable-tie seton: a prospective case series. *ISRN Surgery* 2011;1-5.
23. Abbas T, Nazir A, Sadi W. Management of fistula in ano; Firm cutting seton vs loose seton/ fistulotomy for suprasphincteric and high trans-sphincteric. *Professional Med J* 2009; 16:29-33.
24. Poggio JL. Fistula-in-ano [internet] 2014. Available from: <http://emedicine.medscape.com/article/190234-overview#aw2aab6c14>.
25. Cirocchi R, Santoro A, Trastulli S, et al. Meta-analysis of fibrin glue versus surgery for treatment of fistula in ano. *Ann Ital Chir* 2010; 81:349-56.
26. Shanwani A, Nor AM, Amri N. Ligation of the intersphincteric fistula tract (lift): a sphincter saving technique for fistula in ano. *Dis colon rectum* 2010; 53:39-42.

**CONFLICT OF INTEREST**  
 Authors declare no conflict of interest.  
**GRANT SUPPORT AND FINANCIAL DISCLOSURE**  
 None declared.