
IMAGES IN CLINICAL MEDICINE

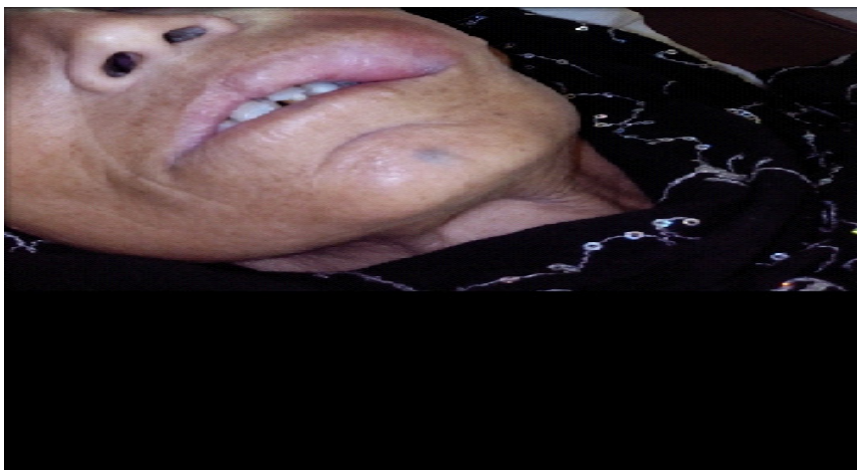


Figure: Photograph of 50 years female with swelling of the upper lip cytologically diagnosed Non-Hodgkin's Lymphoma.

NON HODGKIN'S LYMPHOMA

Non-Hodgkin's lymphoma (NHL) can have extranodal presentation in approximately 25% of cases, unlike Hodgkin's lymphoma which rarely involves extranodal sites. The diagnosis of extranodal lymphoma in the head and neck region can be very difficult as they can mimic more common pathologies such as infection and squamous cell carcinoma. It is important to be aware of extranodal lymphoma as a cause of facial swelling, oral malignant ulcer, or salivary neoplasm. NHL involving the oral cavity is uncommon but it should be considered as a differential diagnosis of other malignant lesions, because treatment and prognosis may vary for individual lesions.

Corresponding Author:

Sajjad Ahmad Baloch
Assistant Professor
Department of Pathology
Gomal Medical College
D.I.Khan, Pakistan
E-mail: sajjadabaloch@gmail.com