

## LYMPHOID LEUCOSIS IN CHICKEN–LIVER HISTOPATHOLOGY

Aly Khan<sup>1</sup>, Muhammad Akram<sup>2</sup>, Noor-un-Nisa<sup>3</sup>, Nasira Khatoon<sup>4</sup> and Mian Sayed<sup>5</sup>

<sup>1</sup>*Crop Diseases Research Institute, PARC, University of Karachi, Karachi-75270, Pakistan*

<sup>2</sup>*Micro Laboratories, 522 Anam Blessings, Shahra-e-Faisal, Karachi-75350, Pakistan*

<sup>3</sup>*Vertebrate Pest Control Institute, SARC, PARC, Karachi University Campus, Karachi-75270, Pakistan,*

<sup>4</sup>*Department of Zoology, University of Karachi, Karachi-75270 Pakistan*

<sup>5</sup>*Department of Zoology, Hazara University, K.P., Pakistan*

---

### ABSTRACT

The avian leucosis virus induces lymphoma in chicken called lymphoid leucosis. This disease causes severe loss due to mortality of poultry birds and depressed performance. The avian leucosis virus (ALV's) are prevalent throughout the world. The present paper describes histopathology of liver with lymphoid leucosis. Four commercial egg type white dead birds, thirty three weeks old with no previous sign of ill health were received from a commercial layer poultry farm of Karachi. On *post mortem* the liver was enlarged. A portion of liver was preserved in 10% formalin and processed for histological studies. Dehydration was carried out in serial concentration of known volume of ethanol. Dehydrated tissue was then imbedded in paraffin wax at 52°C for 12 days. During the wax infiltration process air bubbles were removed from the tissue. Using rotary microtome 10 µm thick sections were cut and stained with haematoxylin and eosin. Photomicrographs were taken using an automatic photographic camera mounted on a microscope Nikon Optiphot-2. The sections of liver show heavy infiltration of lymphoid cells. The infiltration of cells in the liver was marked where there was loss of hepatocytes. Lymphoid cells at high magnification revealed that the cells consisted of small and large lymphocytes with scanty and ample cytoplasm. The scanty cytoplasm of large lymphocytes appears poorly stained while the small lymphocytes present are deeply stained. There is no definitive treatment for lymphoid leucosis available.

**Keywords:** Liver, chicken, lymphoid leucosis, Karachi, histopathology.

---

### INTRODUCTION

The avian leucosis virus induces lymphoma in chicken called lymphoid leucosis (Pizer and Humphries, 1989). Tumors occur in liver, spleen, kidneys, ovaries, bursa and bone. It causes severe losses due to mortality of birds and depressed performance. The avian leucosis virus (ALV's) are prevalent throughout the world, new strains from one locality may spread across borders undermining the disease control measures. It is either transmitted through egg or brought in from adult infected birds to young egg borne or transmitted to very young chicken from infected older birds. In birds 16 weeks or older the symptoms are extreme depression leading to death. In birds over 6 months of age, death without symptoms or pale shriveled comb, loss of appetite and diarrhea, weakness, sometimes bluish comb, vent feathers spotted with white (ovates) or green (bile), enlarged liver, kidney or nodular tumors through skin. Reduced egg production, weight loss and green droppings are common symptoms (McMullin, 2004). In the present study histology of chicken liver is being reported based on clinical and pathological features characteristic of avian leucosis.

### MATERIALS AND METHODS

Thirty three weeks old four commercial egg laying dead birds were received from a commercial layer poultry farm of Karachi. The birds had no previous symptoms of ill health. On *post mortem* examination, the liver was diffusely enlarged. A portion of infected liver was preserved in 10 percent formalin and procured for histological studies. Dehydration was carried out in serial concentrations of known volume of ethanol. Dehydrated tissue was then embedded in paraffin wax at 52°C for 12 days. During the wax infiltration air bubbles were removed. Using a rotary microtome 10 µm thick sections were cut. The sections were stained with haematoxylin and eosin. Photomicrographs were taken using an automatic photographic camera mounted on a microscope Optiphot-2 in the Department of Zoology, University of Karachi.

### RESULTS AND DISCUSSION

The main finding in the section of the liver was diffuse heavy infiltration of lymphoid cells. The infiltration of cells in the liver was marked where there was loss of hepatocytes (Fig. 1), a high magnification of lymphoid cells revealed that the cells consisted of small and larger lymphocytes with scanty and ample cytoplasm. The scanty

cytoplasm of large lymphocytes appears poorly stained while the small lymphocytes present are deeply stained (Fig. 2). Balachandran *et al.* (2009) reported that lesion suggestive of lymphoid leucosis was observed in 15 tissues (2.16%) of layer birds, their study revealed that the lymphoid leucosis involved liver (26.67%) and spleen (73.33%) tissues. However, no incidence was of lymphoid leucosis was reported in broiler birds. In the present study no neural involvement was present, while in Marek's disease neural involvement is a conspicuous feature (Halliwell, 1971). There is no definitive treatment for lymphoid leucosis, howsoever, it can be controlled by the following practices (a) Buying and breeding resistant strains (heavier birds are more resistant than lighter laying birds, (b) Identify and eliminate breeders that produce infected birds, (c) Do not mix younger birds with older birds, (d) Not reusing chicken boxes, (e) Isolate sick or infected birds, (f) Thoroughly cleaning of cages before introducing new birds and (g) Good care and limiting stress.

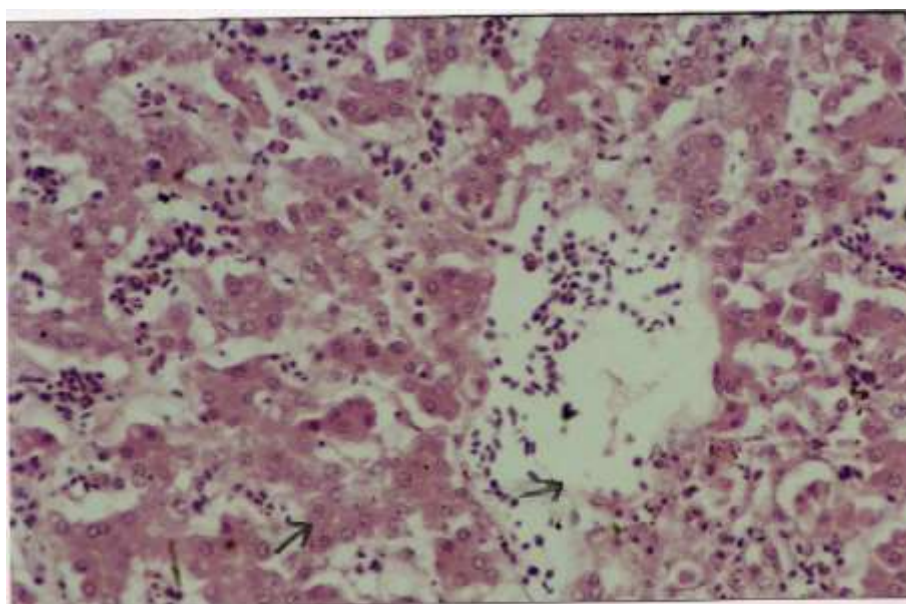


Fig.1. Main histopathological changes was diffuse heavy infiltration of lymphoid cells (↔) and loss hepatocytes (↔) (x 100).

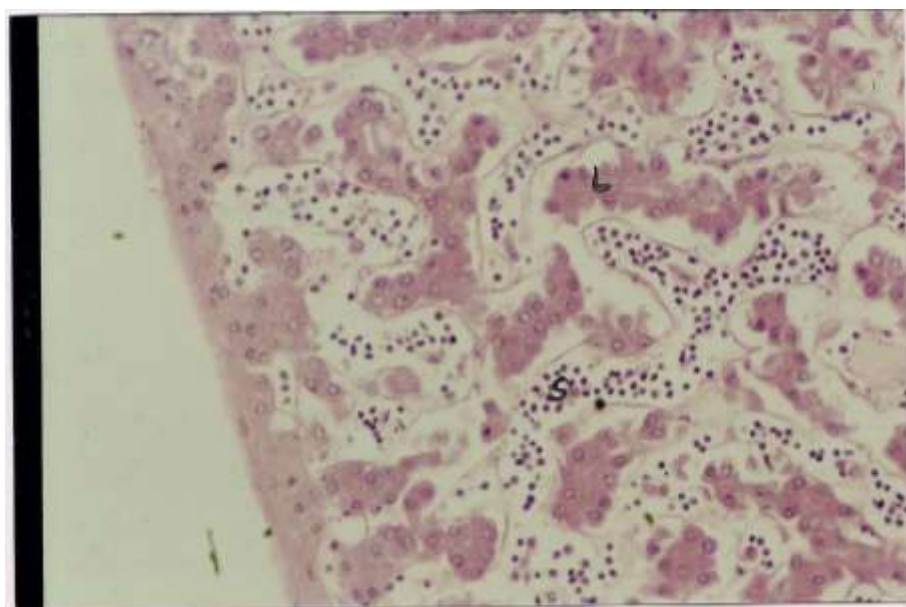


Fig.2. Section showing large lymphocytes (L) poorly stained and small lymphocytes (S) deeply stained (x 100).

**REFERENCES**

- Balachandran, C., N. Paznanivel, S. Vairamuthu and B.M. Manohar (2009). Marek's disease and lymphoid leucosis in chicken – A histopathological survey. *Tamilnadu J. Veterinary & Animal Sciences*, 5: 167-170.
- Halliwell, W.H. (1971). Lesion of Marek's disease in great horned owl. *Avian Diseases*, 15: 49-55.
- McMullin, P. (2004). *A packet guide to poultry health and disease*. 5 M Enterprises Ltd., England. Pp. 278
- Pizer, E. and E.C. Humphries (1989). RAV-I insertional mutagenesis. Disruption of the c-myc locus and development of avian B-cell lymphomas. *Journal of Virology*, 63: 1630-1640.

(Accepted for publication August 2011)