

Comparison of Three-Dimensional Plates Versus Conventional Two Miniplates For Open Reduction and Internal Fixation of Mandibular Symphysis and Parasymphysis Fractures

Khurram Jah Zafar, Maleeha Khurram, Omer Sefvan Janjua, Muhammad Imran Saleh, Saira Khalid, Muhammad Usman Khalid, Rida Ahmed

ABSTRACT

Objectives: To compare the efficacy of single 3-D miniplates over conventional 2 miniplates for open reduction and internal fixation of mandibular symphysis and parasymphysis fractures. **Study Design:** A prospective randomized clinical study. **Settings:** Department of Oral and Maxillofacial Surgery, Faisalabad Medical University/ Allied Hospital Faisalabad. **Duration:** April 2017 to April 2018. **Methodology:** A total of 32 patients with mandibular symphysis and parasymphysis fractures were included in the study. Patients were randomly divided into 2 groups. In Group A single 3-D plates were placed while in Group B 2 miniplates were placed. All patients were followed up for 3 months postoperatively. The efficacy of 3-D miniplates over conventional miniplates was measured regarding following parameters: Infection, wound dehiscence, postoperative malocclusion, segmental mobility and nerve deficit. **Results:** The mean operating time for Group A was 8.469 minutes (\pm SD of 1.9102) and for Group B mean operating time was 14.688 minutes with (\pm SD of 1.4245). Out of 16 patients treated by conventional 2 miniplates, 5 patients (31.2%) developed infection, 1 patient had wound dehiscence (6.25%), 4 patients developed occlusal discrepancy (25.0%), another 4 (25.0%) had postoperative segmental mobility and 1 patient (6.25%) developed neurological deficit. Whereas out of 16 patients treated by 3-D plate 2 patients (12.5%) developed infection, 1 patient (6.25%) each presented with wound dehiscence and occlusal discrepancy, whereas no patients (0.00%) had postoperative segmental mobility and neurological deficit. **Conclusion:** The results of this study confirmed that single 3-D plate osteosynthesis was comparable to conventional 2 miniplate osteosynthesis in fixation of mandibular symphysis and parasymphysis fractures. Both systems provided enough stability for proper bone healing, and there was no pronounced difference between the two groups with regard to the outcomes of infection, wound dehiscence, postoperative malocclusion, segmental mobility and neurological deficit. The only statically significant result was of mean operating time for group A that was less compared to group B.

Key Words: Mandibular fracture, Infection, Wound dehiscence.

Corresponding Author

Submitted for Publication: 14-05-2018

Accepted for Publication: 16-09-2018

DR. KHURRAM JAH ZAFAR, Senior Registrar, Oral & Maxillofacial Surgery, Dental Section, Faisalabad Medical University, Faisalabad-Pakistan
Contact / Email: +92 333-6512377, drkhurram1982@hotmail.com

Citation: Zafar KJ, Khurram M, Janjua OS, Saleh MI, Khalid S, Khali MU, Ahmed R. Comparison of Three-Dimensional Plates Versus Conventional Two Miniplates For Open Reduction and Internal Fixation of Mandibular Symphysis and Parasymphysis Fractures. APMC 2019;13(1):51-5.

INTRODUCTION

The modern era of fast moving, result oriented life style has made a strong impact on the society. Road traffic accidents, assaults, gunshot injuries and sport injuries had an alarming increase in the past four decades and are a cause of great concern.^{1,2} Trauma to maxillofacial region is very common in all these unfortunate events.¹

The prominent position of the mandible on the face makes it vulnerable to these types of injuries and accounts for 15.5%-59% of all facial injuries. Mandible is therefore one of the most commonly fractured facial bones.^{1,3} Among mandibular fractures in adults, mandibular symphysis and parasymphysis are one of the most frequently fractured sites that accounts for 18-20%, followed by mandible angle and condyle fractures.^{1,4}

The goal of mandibular fracture treatment is the restoration of anatomical form and function with establishment of the proper occlusion.⁴ The management of symphyseal and parasymphyseal mandibular fractures has progressed remarkably over the past many years. Historically mandibular

fractures were managed with closed reduction followed by prolonged maxillomandibular fixation (MMF).^{2,4}

In the past few decades there has been an increasing research in achieving early return to normal function by applying different techniques of direct fixation with an open approach and allowing direct anatomical reduction of the fracture segments.⁵ Hence there has been a paradigm shift from simple MMF to ORIF as a standard treatment modality. Various options for ORIF have been developed over the years like miniplates, lag screws, 3-D plates, bioresorbable plates etc.^{1,2,5,6}

Currently modifications in miniplates like titanium three-dimensional (3-D) plating system have been introduced to counter the shortcomings of semirigid fixation with fewer complications.⁵ In 1992 Mustafa Farmand first introduced the 3-D plating system with the edge of providing three-dimensional stability of the fractured and osteotomized bony segment.^{1,2,5,7}

The newly developed 3-D plating system provides ultimate advantages over conventional miniplates. The 3-D plating system uses lesser plates and screws as compared to

conventional miniplates to hold the fractured bone segments. In case of conventional miniplates two plates are recommended in the management of symphysis and parasymphysis fractures while only one 3-D plate is necessary for the same treatment. Therefore 3-D plates use lesser hardware and as well as also shortens the overall operation time.^{1,5,7,8}

Considering the above background knowledge this study was conducted to compare and evaluate double miniplates osteosynthesis with 3-D plates in terms of treatment outcome in the management of symphysis and parasymphysis fractures.^{7,9} This study will guide the clinicians in selecting a better plating system to treat symphysis and parasymphysis fractures and results will be popularized in public for their benefit.

METHODOLOGY

Study Design: Prospective randomized clinical study.

Settings: Oral and Maxillofacial Surgery Department, Faisalabad Medical University / Allied Hospital Faisalabad.

Duration: One year from April 2017 to April 2018.

Methods: A total of 32 patients were included in the study. All the patients were treated on in-patient basis.

Inclusion Criteria:

- a) Mandibular fracture involving symphysis, parasymphysis without other associated fracture of the mandible.
- b) Fractures indicated for open reduction and internal fixation.

Exclusion Criteria:

- a) Comminuted fractures
- b) Malunited fractures
- c) Fracture sites with sign of infection e.g. pus discharge
- d) Pediatric patients below 12 years of age and geriatric patients with complete edentulous mouth
- e) Patients with immune-compromised status e.g. diabetes and steroid therapy
- f) Patients who were not willing to return for follow up.

Methods: The study was approved by ethical committee of Faisalabad Medical University and informed consent was obtained from the patients before their inclusion in the study.

All the patients presented to the oral & maxillofacial surgery department for the management of mandibular fracture were subjected to complete history taking followed by clinical examination of oral & maxillofacial region. The oral cavity was cleaned of blood clots, tooth fragments and other debris. A temporary stabilization of fracture segments was provided when considered necessary. The face and the oral cavity were examined for signs of soft tissue lacerations. All wounds were cleaned and lacerated wounds were sutured using 3-0 silk. As a prophylaxis injection tetanus toxoid (TT) 0.5ml was administered and patients were kept on antibiotics and analgesics. Routine pre-operative investigations were advised and relevant radiographs were taken. All the patients were examined and treated by the same oral and maxillofacial surgeon. The patients were divided randomly into two groups of 16 patients each. Group A was treated with open reduction and internal fixation using 3-D miniplates and Group B were treated with conventional two miniplates.

Surgical Technique: All patients were given general anesthesia via nasoendotracheal intubation.^{2,8} Local infiltration of lignocaine 2% with adrenaline 1:100,000 for hemostasis was used at the incision site. A standard trans-oral surgical technique was followed in both the groups for exposure and reduction of the fracture segments.¹ To establish pre-injury occlusion MMF was done by arch bar or eyelet wiring.⁴ Once normal occlusion was achieved, fracture segments were fixed with either 3-D 2mm eight holes plate (group A) or conventional 2mm two miniplates, 5 holes each (group B) following Champy's principle of osteosynthesis using monocortical screws.^{1,6,8}

In group A the 3-D plates were adapted in such a manner that the horizontal bar was perpendicular to the fracture line and the vertical ones parallel to it, the plate was placed in the neutral zone on the lateral cortex (Figure: 1). In group B patient's one miniplate was fixed 5 mm below the apices of teeth and another inferior to the first plate to resist torsional forces in anterior region of mandible (Figure: 2). In both the type of plating 2x8 mm monocortical screws were used to stabilize the plates.⁶ After achieving the adequate haemostasis the incision was closed in layer wise fashion using 3-0 vicryl suture.^{5,6} The time required for the adaptation and fixation of the plate at the fracture segment was noted for both the groups.¹

Postoperative MMF was done for 2 weeks in both the groups. All patients received postoperative antibiotics and analgesics for 7 days and were advised to take soft diet for 4 weeks. Oral hygiene maintenance using 0.2% chlorhexidine mouthwash was also advised to all the patients in postoperative period.^{1,4,5}

Postoperative Assessment: Patients were followed for a period of 3 months at the interval of 1 week, 2-week, 4-week, 8 week and 3 months for infection, wound dehiscence, segmental mobility, postoperative occlusion and neurological deficit.¹ All the parameters used were assessed at various postoperative visits and noted, postoperative orthopantomogram (OPG) was taken if needed in any patient. In order to eliminate the intra-observer error analysis and follow up were performed by the same surgeon.⁸ All the complications when appear were managed accordingly.⁵

Statistical Analysis: The above mentioned findings were recorded, tabulated and statistically analyzed using SPSS version 17 software (SPSS, Inc., Chicago, IL, USA). Student's *t* test was used to compare clinical benefit of using 3-D plates and conventional miniplates in the treatment of mandibular symphysis and parasymphysis fractures. Mean frequencies and percentages were calculated for infection, wound dehiscence, malocclusion, segmental mobility and neurological deficit whereas mean and standard deviation was calculated for mean operating time among both the groups. *P* value < 0.05 was considered statistically significant.^{1,6,8}

RESULTS

Total 32 patients with symphysis and parasymphysis fracture of mandible were enrolled in this study. The age of patients ranged from 16 years to 54 years with mean age of 32.4 years. Out of 32 patients there were 23 males and 9 female's patients. Table 1

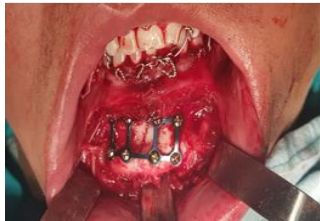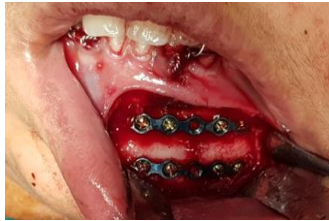Table 1: Gender distribution of patients

Gender	No. of patients	Percentage
Male	23	71.9%
Female	9	28.1%
Total	32	100.0%

Road traffic accident (RTA) was the main case of trauma in 23 patients out of 32 patients followed by assault 4 patients, fall 4 patients and sports injury 1 patient. Table 2

Table 2: Pattern of etiology of fractures in the present study

Etiology	No. of patients	Percentage
Road traffic accident	23	71.9%
Assault	4	12.5%
Fall	4	12.5%
Sports Injury	1	3.1%
Total	32	100.0%

**Figure 1: 3-D plate fixation at parasymphysis fracture****Figure 2: Conventional 2 miniplate fixation at parasymphysis fracture**

In this study parasymphysis is the most frequent site of fracture, 27 out of 32 patients (84.4%) had parasymphysis fracture, while remaining 5 patients (15.6%) had symphysis fracture. Table 3

Table 3: Distribution of mandibular fracture according to site

Site of Fracture	No. of patients	Percentage
Parasymphysis fracture	27/32	84.4%
Symphysis fracture	5/32	15.6%

The mean duration between time of trauma and consultation at the hospital was 2 days and mean duration between first consultation and operation was 4 days including both the groups. The mean operating time of the procedure was 8.4 minutes (\pm SD 1.9102) for Group A and 14.6 minutes (\pm SD1.4245) for Group B patients. Table 4

Table 4: Comparison of operating time

Type of plating	N	Mean	Std. Deviation	Std. Error Mean
Operating time 3-D Plate	16	8.469	1.9102	.4776
Miniplate	16	14.688	1.4245	.3561

The outcome of Postoperative parameters like infection, wound dehiscence, postoperative malocclusion, segmental mobility and neurological deficit were checked at the interval of 1 week, 2 weeks 4 weeks, 8 weeks and 3 months in both the groups and results are shown in Table 5.

Table 5 Outcome of parameters between Group A and Group B

Parameter Type of Plating		1 st Week	2 nd Week	3 rd Week	4 th Week	8 th Week	P Value t test
Infection	3-D plating	2/16 (12.5%)	0/16 (0.00%)	0/16 (0.00%)	0/16 (0.00%)	0/16 (0.00%)	0.212
	Miniplate	5/16 (31.2%)	1/16 (6.25%)	0/16 (0.00%)	0/16 (0.00%)	0/16 (0.00%)	
Wound Dehiscence	3-D plating	1/16 (6.25%)	1/16 (6.25%)	1/16 (6.25%)	0/16 (0.00%)	0/16 (0.00%)	1.000
	Miniplate	1/16 (6.25%)	1/16 (6.25%)	1/16 (6.25%)	0/16 (0.00%)	0/16 (0.00%)	
Malocclusion	3-D plating	1/16 (6.25%)	1/16 (6.25%)	1/16 (6.25%)	0/16 (0.00%)	0/16 (0.00%)	0.154
	Miniplate	4/16 (25.0%)	3/16 (18.7%)	1/16 (6.25%)	0/16 (0.00%)	0/16 (0.00%)	
Segmental Mobility	3-D plating	0/16 (0.00%)	0/16 (0.00%)	0/16 (0.00%)	0/16 (0.00%)	0/16 (0.00%)	0.033
	Miniplate	4/16 (25.0%)	3/16 (18.7%)	0/16 (0.00%)	0/16 (0.00%)	0/16 (0.00%)	
Neurological Deficit	3-D platin	0/16 (0.00%)	0/16 (0.00%)	0/16 (0.00%)	0/16 (0.00%)	0/16 (0.00%)	0.341
	Miniplate	1/16 (6.25%)	1/16 (00%)	1/16 (6.25%)	1/16 (0.00%)	0/16 (0.00%)	

DISCUSSION

During the last 10 years there has been immense progress in surgical techniques, armamentarium and materials in the discipline of oral and maxillofacial surgery wherein ORIF has almost become standard practice.^{6,11} ORIF by means of conventional miniplates is one of the frequently used treatment methods to treat mandibular symphysis and parasymphysis fractures. The disadvantages of conventional miniplates have led to the development of 3-D miniplates. The 3-D plates have

various advantages over miniplates like more rigidity, less foreign material, less time in application etc.^{3,6,12}

This study consisted of total 32 patients, out of which 23 were male and 9 were female. This male supremacy was also reported by other studies like Kumar et al¹ and Sadhwani et al.⁷ This may be determined by the fact that the males are more susceptible to conditions which are associated with high possibility of trauma.¹ The age group most commonly affected in our study was 16-54 years with the mean age of 32.4 years. Mean age of the patients in other studies were as follows: 30.9

years in the study of Gokkulakrishnan et al² and 24.5 years in the study of Al-Tairi et al.⁵

RTA was the cause of mandibular fractures in 23 (71.9%) cases, fall in 4 cases (12.5%), assault in 4 cases (12.5%) and in 1 case (3.1%) it was sports injury. This distribution compared favorably with the results obtained by Al-Tairi et al¹ and Kumar et al.² Other studies in developed countries (USA & Australia) reported assault as the major cause of mandibular fractures (69-90%).² The factors contributing to this variation could be due to bad roads, poor implementation of traffic rules and not using safety measures in developing countries.^{1,2,13,14,15}

In this current study parasymphysis was the most frequent fracture. Parasymphysis fracture accounts for 84.4% fractures in this study followed by symphysis fracture 15.6%. This result was in accordance with the findings of Balakrishnan⁴ who reported 78% parasymphysis and 22% symphysis fractures in their study and Malhotra et al¹³ reported 90% of parasymphysis and 10% of symphysis fractures.^{1,4,13}

In this study the operating time needed for the adaptation and fixation of 3-D plate was between 6 to 12 minutes with the mean time of 8.4 minutes and for the conventional 2 miniplates ranged from 12 to 16.5 minutes with a mean of 14.6 minutes. According to the studies by Kumar¹, Kinra¹¹ and El Nakeeb¹² they also reported decreased operating with 3-D plates as compared to 2 conventional miniplates for the fixation of mandibular symphysis and parasymphysis fractures.^{1,11,12,15} Conventional 2 miniplates required higher time because they are linear plates and two plates are required separately for fixation of the fracture. On the other hand, 3-D plate due to its geometric configuration stabilize the fracture simultaneously at superior and inferior borders at a time thus time is saved in fixation of plate.^{1,9,10,16} The only potential limitation of 3-D plates may be costly implant material due to incorporation of the extra vertical bars for controlling the torque forces and in cases where the fracture line passing through the mental foramina area.⁹

Among patients in group A, only 2 patients out of 16 showed signs of infection at 1 week follow up which was managed conservatively by local irrigation, debridement, and antibiotics. At 2nd week and onward follow ups at 4th, 8th and 12th week there were no sign of infection in previously infected patient. Whereas in group B initially 5 patients presented with infection at 1st week follow-up which was reduced to 1 patient till 2nd week follow up and at 4th, 8th and 12th week no patient showed further signs of infection. Thus, there is no statically significant difference between both the groups. No incidence of plate failure was reported in both the groups which correspond with the report by Sadhwani et al⁷. On the other hand, this result was contradictory to the findings of Jain et al¹⁰ in which 2 miniplates out of 14 were removed due to unresolved infection, thus considering miniplates inferior to the 3-D plates.^{7,10,16,17}

In this study postoperatively two patients one in each group showed the wound dehiscence at 1st week, 2nd week and 4th week follow up. Inadequate tissue available during suturing which resulted in tension at the wound closure site and post-operative infection leads to wound breakdown. Both the patients

were kept on antibiotics and continued follow up in the outdoor patient department for normal saline and povidine-iodine irrigations, which lead to satisfactory secondary healing at 8th and 12th week of follow up. There is no statically significant difference between the two plating systems in this particular study. These results are in accordance with the results of Kumar et al¹ and Vivek et al⁶ which showed the similar results regarding wound dehiscence in comparison of 3-D plates with conventional miniplates.

The occlusion of patients was checked preoperatively and during the follow up visits after surgery. Among Group A, only 1 patient and in Group B, 4 patients developed postoperative malocclusion which was corrected by postoperative MMF for 4-week duration. At the end of 12th week no patient in either group had malocclusion. The results of postoperative malocclusion were compared between both the plating groups and results showed no statically significant difference.

Mobility of fractured segments was evaluated in both groups: In Group B, 4 patients had segmental mobility at 1st week follow up and at 2nd week follow up only 3 patients had segmental mobility. All the patients with segmental mobility were treated with MMF for 4 weeks. In Group A none of the patients had postoperative segmental mobility present at the fracture site. The results however showed no statistically significant difference among the two groups. According to Sadhwani⁷ 3-D plates provides relatively increased torsional stability and also anterior mandibular fractures are under greater degree of torsional strain than any other area of mandible that may lead to postoperative segmental mobility.⁷

In Group B neurological deficit was reported in 1 patient only due to nerve entrapment in the fracture segment which was retrieved during the operation and was sutured using 5-0 prolene. Postoperatively patient showed complete neurological signs of recovery at 12 weeks follow up. While in Group A none of the patient showed neurological deficit. The statistical analysis showed no difference in the two plating systems in regard to nerve injury. These results are comparable with the results of Kumar¹ and Liu et al³.

CONCLUSION







Thus, it can be concluded from this study that single 3-D plate is comparable to conventional 2 miniplates in open reduction and internal fixation of mandibular symphysis and parasymphysis fractures. Both systems provided enough stability for proper bone healing, and there was no pronounced difference between the two groups with regard to the outcomes of infection, wound dehiscence, postoperative malocclusion, segmental mobility and neurological deficit. The only statically significant result was of mean operating time for Group A that was less compared to Group B.

REFERENCES

1. Kumar BP, Kumar J, Mohan AP, Venkatesh V, Kumar R. A comparative study of three-dimensional stainless-steel plate versus stainless steel miniplate in the management of mandibular parasymphysis fracture. J Bio Innov. 2012;1(2):19-32.

2. Al-Tairi NH, Shoushan MM, Khedr MS, Abd-alal SE. Comparison of three-dimensional plate versus double miniplate osteosynthesis for treatment of unfavorable mandibular angle fractures. *Tanta Dental Journal*. 2015;12(2):89-98.
3. Liu Y, Wei B, Li Y, Gu D, Yin G, Wang B, Xu D, Zhang X, Kong D. The 3-dimensional miniplate is more effective than the standard miniplate for the management of mandibular fractures: a meta-analysis. *Eur J Med Research*. 2017;22(1):5.
4. Balakrishnan R, Ebenezer V. Three-dimensional titanium mini plates in management of mandibular fractures. *Bio and Pharma J*. 2015;7(1):241-6.
5. Gokkulakrishnan S, Singh S, Sharma A, Shahi AK. An analysis of postoperative complications and efficacy of 3-D miniplates in fixation of mandibular fractures. *Dent Res J* 2012;9(4):414-21.
6. Vivek GK, Shetty A, Vaibhav N, Imran M. A comparative study of single 3-D titanium plate versus conventional Champy's 2 miniplate fixation in the management of mandibular anterior fracture: A prospective clinical study. *J Adv Clin Res Insights* 2016;3(1):194-199.
7. Sadhwani BS, Anchlia S. Conventional 2.0 mm miniplates versus 3-D plates in mandibular fractures. *Ann Maxillofac Surg*. 2013; 3(2): 154-9.
8. Al-Moraissi EA, Mounair RM, El-Sharkawy TM, El-Ghareeb TI. Comparison between three-dimensional and standard miniplates in the management of mandibular angle fractures: a prospective, randomized, double-blind, controlled clinical study. *Int J Oral Maxillofac Surg*. 2015;44(3):316-21.
9. Budhraj NJ, Shenoi RS, Badjate SJ, Bang KO, Ingoale PD, Kolte VS. Three-dimensional locking plate and conventional miniplates in the treatment of mandibular anterior fractures. *Ann Maxillofac Surg*. 2018;8(1):73-7.
10. Jain GC, Jain R, Dwivedi H. A comparative evaluation of bite force as a parameter for the stability in conventional and three-dimensional mini plates. *Ind J Dental Sci*. 2018;10(3):133-8.
11. Kinra PK, Jayakumar K, Soumithran CS, Michael MJ, Passi D, Singh M. Comparative evaluation of bite force analytical study following mandibular osteosynthesis using three-dimensional and conventional locking miniplates. *Natl J Maxillofac Surg*. 2017;8(1):34-40.
12. El Nakeeb NA, El Dibany MM, Shokry MM. A Comparative Study between 3-D Plates and Conventional Miniplates for Internal Fixation of Anterior Mandibular Fractures. *Alex Dental J*. 2016;41(3):253-60.
13. Malhotra K, Sharma A, Giraddi G, Shahi AK. Versatility of titanium 3D plate in comparison with conventional titanium miniplate fixation for the management of mandibular fracture. *J Maxillofac Oral Surg*. 2012;11(3):284-90.
14. Ali Z, Shakeel J, Furqan M. Mandibular Symphysis Fractures; Comparison of Conventional Mini Plates Versus 3d Mini Plates in The Fixation of Isolated Mandibular Symphysis Fractures in Abbasi Shaheed Hospital Karachi--A Clinical Study. *Pro Med J*. 2018;25(6).
15. de Oliveira KP, de Moraes PH, da Silva JS, de Queiroz WF, Germano AR. In vitro mechanical assessment of 2.0-mm system three-dimensional miniplates in anterior mandibular fractures. *Int J Oral Maxillofac Surg*. 2014;43(5):564-71.
16. Sehgal S, Ramanujam L, Prasad K, Krishnappa R. Three-dimensional v/s standard titanium miniplate fixation in the management of mandibular fractures--A randomized clinical study. *J Craniomaxillofac Surg*. 2014;42(7):1292-9.
17. Singh A, Arunkumar KV. Standard 3D Titanium Miniplate Versus Locking 3D Miniplate in Fracture of Mandible: A Prospective Comparative Study. *J Maxillofac Oral Surg*. 2016;15(2):164-72.

AUTHORSHIP AND CONTRIBUTION DECLARATION

AUTHORS	Contribution to The Paper	Signatures
Dr. Khurram Jah Zafar Senior Registrar, Oral & Maxillofacial Surgery, Dental Section, Faisalabad Medical University, Faisalabad	Study Conception and Design, Critical Revision	
Dr. Maleeha Khurram Assistant Professor, Science of Dental Materials, University Medical & Dental College, Faisalabad	Proof Reading and Acquisition of Data	
Dr. Omer Sefvan Janjua Associate Professor, Oral & Maxillofacial Surgery, Dental Section, Faisalabad Medical University, Faisalabad	Data Collection and Data Analysis	
Dr. Muhammad Imran Saleh Assistant Professor, Oral & Maxillofacial Surgery, de' Montmorency College of Dentistry, Lahore	Literature Search and Review	
Dr. Saira Khalid Assistant Professor, Science of Dental Materials, de' Montmorency College of Dentistry, Lahore	Drafting of Article and Tabulation of Results	
Dr. Muhammad Usman Khalid Associate Professor, Oral & Maxillofacial Surgery, Dental Section, Faisalabad Medical University, Faisalabad	Data Collection	
Dr. Rida Ahmed Department of Orthodontics, University of Lahore, Lahore,	Reviewing of Manuscript	