

Synovial Hemangioma of The Ankle Joint - A Rare Entity

Sahar Iqbal, Tahmina Gul, Sadaf Zahid, Naila Atif and Ikram-ul-Haq
Department of Histopathology, Azra Naheed Medical college, Lahore

Abstract: Synovial hemangioma is a rare benign tumor of vascular origin usually effecting joint spaces and tendon sheaths. Patient may present with non-traumatic pain and swelling, sometimes giving the clinical impression of bursitis. Rarity of the condition, vague clinical symptoms and non-specific radiological findings may lead to delayed diagnosis. We present a case of synovial hemangioma of ankle joint which is quite an infrequent site for this lesion.

Keywords: Hemangioma, ankle joint, synovium

Introduction

Synovial hemangioma is a well-recognized but still a rare entity involving the knee and hip more frequently, whereas the wrist, hand and ankle are less commonly involved.¹ Anatomically the lesion can be synovial, juxta-articular or intermediate in nature. The involvement of synovium can be diffuse or pedunculated.² The presenting complaints range from nonspecific symptoms like pain, swelling and stiffness to non-traumatic recurrent hemarthrosis or rarely as a palpable mass.³ These vague clinical symptoms, non diagnostic radiological and laboratory findings are the root cause of delay in the diagnosis of this condition. This delay becomes even more pronounced when the patient belongs to rural area with lack of awareness and scarcity of medical facilities.⁴ Early diagnosis and prompt treatment can reduce joint damage and morbidity.⁵

Case Report

A 12 years old boy presented in the surgical OPD of Chaudhary Muhammad Akram Teaching and Research Hospital, Lahore with the complaints of pain and swelling over the lateral aspect of right ankle for the last 6 months. There was no previous history of any trauma. On examination a soft cystic non-tender well defined swelling was noted anterior to the lateral malleolus measuring 4x3cm. X-Rays of the right ankle revealed no underlying bony abnormality.

Correspondence Author:

Sahar Iqbal

Department of Histopathology,
Azra Naheed Medical college, Lahore

Email: sahar_moeed@hotmail.com

gultahmina@gmail.com

Based on the above-mentioned findings provisional diagnosis of bursal cyst was made. Elective surgical excision of the swelling was done in the surgical department and the specimen was sent to Histopathology department of Azra Naheed Medical College. Gross examination of the specimen revealed a tan brown soft cystic piece of tissue measuring 3.5x3x1cm. Cut surface was tan brown with small cystic spaces. Representative sections were taken and routine histopathological processing was done. Microscopic examination of hematoxylin and eosin stained sections revealed fragments of synovial membrane, hyalinized fibrous tissue comprising of a lesion having admixture of variable sized blood vessels and capillaries mostly arranged in lobular pattern. Thus, the histopathological diagnosis of synovial hemangioma was made.

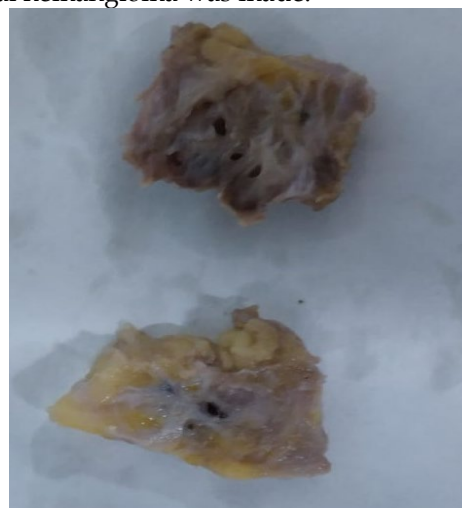

Figure 1: Gross picture showing tan brown lesion with cystic spaces

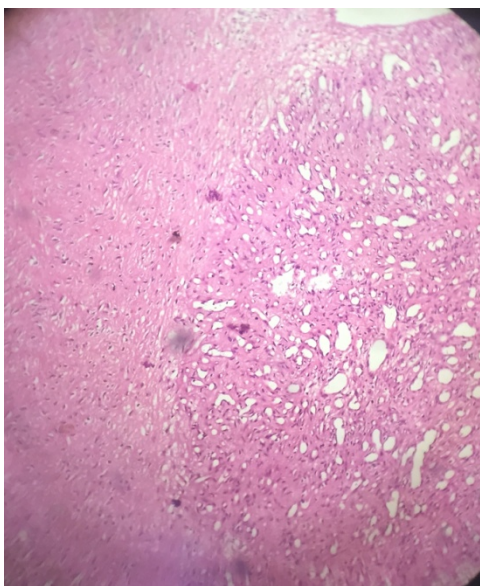


Figure 2A: photomicrograph showing capillary sized vascular spaces arranged in lobular pattern. (H&E 10X)

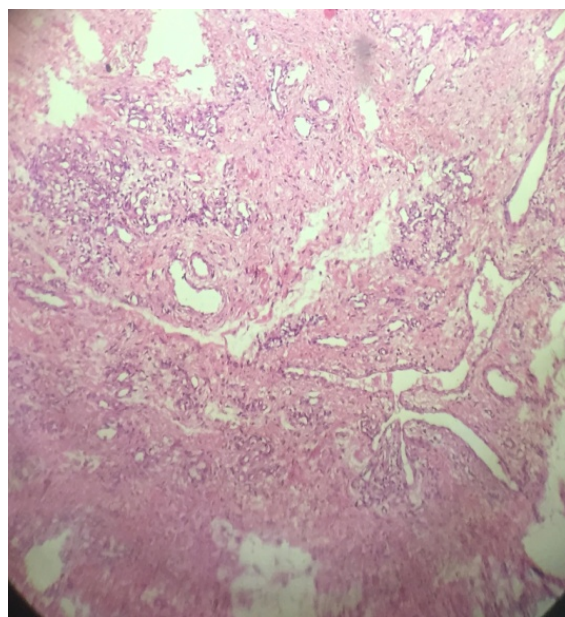


Figure 2B: photomicrograph showing variable sized blood vessels separated by hyalinized stroma. (H&E 10X)

Discussion

Synovial hemangioma, an uncommon benign lesion was first reported in 1856 by Bouchut. Uptill now approximately 200 cases have been documented in the literature.⁶ It is more commonly diagnosed in children and adolescents with the highest frequency of involvement of the knee joint, other joints like ankle, wrist, elbow and temporomandibular being effected

the least.^{5, 7} There is still an ongoing debate about the nomenclature and pathogenesis of hemangiomas as to whether these lesions are hamartomatous/malformation or true neoplasms.^{2,3} Articular hemangiomas originate from benign endothelial cells and based on the anatomic location these can be classified into synovial, juxta-articular or intermediate types. Despite of its benign nature, these lesions may not be well circumscribed or encapsulated.¹ Synovial hemangiomas are almost always unilateral. Non-traumatic recurrent hemarthrosis may raise the suspicion towards its diagnosis.⁵ Magnetic Resonance Imaging is superior to conventional plain radiographs in the assessment of the nature of lesion as plain radiographs are normal in almost half of the patients.⁸ Angiography can also be of some help if there is an associated Arteriovenous malformation. However none of radiological modalities is confirmatory.⁹

The gold standard for diagnosis of synovial hemangioma is histopathology.⁹ Histologically these are classified as Capillary, cavernous, venous or mixed.⁷ Gross examination reveals a well circumscribed lesion with a blue-red tinge on cut surface. Diagnostic microscopic features include variable sized blood vessels lined by benign endothelial cells.¹ It is important to differentiate these lesions from histological mimickers that include pigmented villonodular synovitis (PVNS), non-specific synovitis, arthropathies (rheumatoid arthritis, synovial osteochondromatosis and hemophilic arthropathy) and organizing hemorrhage.⁸ The key point to distinguish PVNS from synovial hemangioma is the presence of sheets of histiocytes often laden with cytoplasmic hemosiderin and multinucleated giant cells. Non-specific synovitis reveals mixed inflammatory infiltrate along with perivascular myxoid change. Organizing hemorrhage can also sometimes reveal scattered dilated spaces but in contrast to synovial hemangioma these are not truly lined by endothelial cells.⁹

The management of synovial hemangioma depends on the size and location of the tumor. If the tumor is small, localized and pedunculated arthroscopic excision is the treatment of choice whereas in diffuse lesions open surgery (arthrotomy) is recommended.^{5,8} Few cases may require the need of preoperative consultation of a vascular surgeon for embolization.⁴ In cases where the joint has undergone irreparable damage arthroplasty is required.⁹

Conclusion

The diagnosis of synovial hemangioma is quite challenging due to non-specific clinical and radiological findings. Diagnostic delay can lead to permanent joint damage. Thus, this entity should always be kept in mind when dealing with non-traumatic painful and swollen joints as early diagnosis and management can save the patient from the risk of arthroplasty.

References

1. Tabbal, G., Lee, M., Ziadie, M. et al. Synovial hemangioma of the interphalangeal joint: a case report. *Eur J Plast Surg* (2013) 36: 199-201.
2. Rajni, Khanna G, Gupta A, Gupta V. Synovial hemangioma: A rare benign synovial lesion. *Indian J Pathol Microbiol.* 2008; 51(2):257-8.
3. Amita K, Rajani R, Vijayshankar S, Shobha SN. Synovial hemangioma of the knee joint: a rare case report. *Int J Med Res Health Sci.*2014;3(2):448-50.
4. Bawa A S, Garg R, Bhatnagar k et al. Synovial Hemangioma of the Knee Management and Excellent Outcome 2 Years after Arthroscopic Synovectomy in a 25-year-old Male with a 20-year History. *J Orthop Case Rep.*2017 May-Jun;7(3):17-20.
5. Tahmasebi M N, Sobhan M R, Bashti S K et al. Synovial hemangioma of the knee with recurrent effusion and pain: a Case Report.*Acta Medica Iranica.* 2014;52(8):644-6.
6. Arsalan H, Islamoglu N, Akdemir Z, Adanas C. Synovial hemangioma in the knee:MRI Findings. *J Clin Imaging Sci.*2015;5:23.
7. Oumakhir S1, Ghfir M, El Ktaibi A, Albouzidi A, Sedrati O. Synovial hemangioma of the ankle. *Foot (Edinb).* 2010;20(1):42-3.
8. Vakil-Adli A, Zandieh S, Hochreiter J, Huber M, Ritshechl P. Synovial hemangioma of knee joint in a 12-year-old boy: a case report. *Journal of Medical Case Reports* 2010; 4:105.
9. Mahata M, Gayen R, Dasgupta S et al. Synovial hemangioma of the ankle joint: A rare and unusual encounter. *IJBR.*2015;6(09):726-8.

.HISTORY	
Date Received:	03-10-2018
Date Sent for Reviewer:	20-12-2018
Date Received Reviewers' Comments:	22-12-2018
Date Received Revised Manuscript:	23-12-2018
Date Accepted:	24-12-2018

CONTRIBUTION OF AUTHORS	
Author	CONTRIBUTION
Sahar Iqbal	A, B, C, D
Tahmina Gul	A, B, C, D
Sadaf Zahid	B
Naila Atif	C, E
Ikram-ul-Haq	C, E

KEY FOR CONTRIBUTION OF AUTHORS:

- A. Conception/Study Designing/Planning
- B. Experimentation/Study Conduction
- C. Analysis/Interpretation/Discussion
- D. Manuscript Writing
- E. Critical Review
- F. Facilitated for Reagents/Material/Analysis